

Lateral Decubitus Position for Arthroscopic Suprapectoral Biceps Tenodesis

David M. Burt, M.D.



Abstract: The purpose of this report is to describe arthroscopic suprapectoral biceps tenodesis in the lateral decubitus position. Many technique descriptions for this procedure emphasize the beach-chair position to obtain optimal anterior subdeltoid visualization of the relevant anatomy. This is not required and may be less desirable or comfortable for a shoulder arthroscopist who prefers the lateral decubitus position. Therefore, the aim of this report is to show that the relevant anatomy may be readily and safely accessed, and the procedure effectively performed, in the lateral decubitus position.

Arthroscopic suprapectoral tenodesis has emerged as a valid treatment option for a variety of biceps and related shoulder pathologies.¹⁻⁴ The ideal location and methodology for fixation of the long head of the biceps tendon (LHBT) are debated, yet this technique has proved successful in achieving the primary goals of tenodesis: removal of the tendon from sites of pain and pathologic change,⁵ stable fixation, and approximation of the normal length-tension relation of the biceps muscle.⁶

Many authors advocate the beach-chair position with moderate to high shoulder and elbow flexion angles^{3,7,8} to aid arthroscopic visualization of the anterior subdeltoid anatomy, but this is not mandatory. The relevant anatomic relations that guide localization of the biceps tendon in the suprapectoral region can be readily visualized while in the lateral decubitus position. Moreover, for surgeons who prefer lateral decubitus shoulder arthroscopy, a switch to the beach-chair position only during certain biceps cases may decrease surgeon comfort, increase technical challenge, and

negatively impact the performance of concomitant procedures, such as rotator cuff repair. The purpose of this report is to describe a reproducible and safe method for arthroscopic suprapectoral interference screw fixation of the LHBT in the lateral decubitus position with standard portals ([Video 1](#)).

Operative Technique

The procedure is performed with the patient under general anesthesia with an interscalene block. The patient is positioned in the lateral decubitus position with a beanbag and axillary roll in place. Balanced suspension is used with 10 lb of traction, shoulder abduction of 45°, and forward flexion of 15°. A slight tilt of the head past neutral and away from the operative shoulder is preferred to prevent obstruction of the surgeon's hand and shaver wand during anterior-superior portal work ([Table 1](#)). For surgeons inexperienced with this approach, we recommend practice in a cadaveric laboratory to better understand the potential risks and limitations that one may encounter ([Table 2](#)).

After sterile preparation and draping, a posterolateral viewing portal is made; then, an anterior-superior portal ([Fig 1](#)) is created with needle localization from outside-in through the rotator interval. A complete arthroscopic examination is performed, and associated pathology is treated as indicated. The tendon is not exteriorized during this procedure, so it is advisable to complete the tenodesis prior to any rotator cuff repair to prevent entrapment of the tendon as a result of cuff repair.

Once the decision is made to perform a biceps tenodesis, a 5-mm clear cannula is placed through the anterior-superior portal, allowing passage of a stay

From Midwest Sports Medicine Institute, Burr Ridge, Illinois, U.S.A.

The author reports that he has no conflicts of interest in the authorship and publication of this article. Full ICMJE author disclosure forms are available for this article online, as [supplementary material](#).

Received October 1, 2019; accepted November 17, 2019.

Address correspondence to David M. Burt, M.D., Midwest Sports Medicine Institute, 6860 N Frontage Rd, Burr Ridge, IL 60521, U.S.A. E-mail: amburt@sbcglobal.net

© 2019 by the Arthroscopy Association of North America. Published by Elsevier. This is an open access article under the CC BY-NC-ND license (<http://creativecommons.org/licenses/by-nc-nd/4.0/>).

2212-6287/191191

<https://doi.org/10.1016/j.eats.2019.11.005>

Table 1. Tips and Pearls

Use the lateral decubitus position with a slight head tilt away from the shoulder.
Create standard working portals and a transdeltoid portal 1 cm superior and lateral to the upper axillary fold.
Keep the tendon stay suture close to the hiatus and away from the tenotomy site.
Complete the tenodesis prior to the rotator cuff repair.
Leave the 5-mm cannula in place until the subacromial bursectomy is completed to protect the suture, but remove it for anterior subdeltoid bursectomy.
Elevate the foot of the operating room table slightly if more room is needed to visualize the subdeltoid space.
Note that the typical fluid pressure is around 80 mm during bursectomy.
Pull the tendon to length before insertion, and favor the proximal tendon sliding into the tunnel and the distal tendon folding into the tunnel to avoid over-tensioning.
Leave the screw head 1-2 mm proud to keep the threads engaged in the cortex.

suture into the biceps tendon (Figs 2-6). This suture is placed as close as possible to the biceps hiatus, away from the tenotomy site. A suture-penetrating device grasping a No. 2 nonabsorbable suture at its midpoint is used to pierce the tendon. The suture loop is released, the penetrator is slowly backed out of the tendon, the loop is grasped again by reaching around the tendon, and the loop is pulled out of the cannula. The free tails of the doubled suture are passed through the loop to create a cinch, or "luggage tag," that slides back to the tendon with traction on the tails. Knots may be tied in the suture at this point for added security if desired. An arthroscopic biter or cautery is then used to perform a tenotomy of the tendon near its base, and tissue is debrided with a shaver to the level of the superior labrum (Fig 7).

The arthroscope is moved into the subacromial space, viewing from posterior. A standard anterolateral portal (Fig 8) is made 2 to 3 cm inferior to the anterolateral acromion with the same trajectory as would be required for adequate decompression and acromioplasty. The 5-mm cannula is left in place to protect the stay suture during subacromial bursectomy. After bursectomy, the scope is moved to the anterolateral portal, and the 5-mm cannula may be either removed or retracted to the level of the subacromial space, allowing work to

continue from the anterior-superior portal. The shaver at this time is in a vertical or longitudinal orientation with the arm to perform anterior subdeltoid bursectomy. Proper head position during preoperative setup avoids any obstruction of the shaver wand and surgeon's hand during this portion of the procedure. Care is taken not to use the shaver medial to the conjoined tendon to protect the musculocutaneous nerve, as well as to keep the shaver blade away from the deltoid muscle, avoiding injury to terminal axillary nerve branches (Table 2). Completion of anterior subdeltoid bursectomy brings into view the conjoined tendon medially and the upper border of the pectoralis major inferiorly. The biceps tendon is visualized running vertically within its synovial sheath medial to the pectoralis insertion (Fig 9). In the vast majority of cases, this visual recognition pattern is readily obtained after anterior subdeltoid bursectomy; however, if there is difficulty with visualization, then 10° to 15° of elevation of the foot of the operating room table will bring the shoulder and elbow into slight flexion, which may further open the subdeltoid space. Humeral rotation and/or traction on the stay suture may also help bring the tendon into view.

A narrow biter is used to release the biceps sheath from the inferior portion of the bicipital groove down to

Table 2. Advantages and Limitations**Advantages**

- Maintenance of comfort and consistency for surgeons who prefer lateral position
- No need for open procedure after arthroscopy
- Consistent visualization of surgical anatomy
- Stable fixation in metaphyseal suprapectoral humeral bone

Limitations

- There is a learning curve to achieve successful completion of this procedure, and cadaveric practice is strongly recommended.
 - Some cases may not provide adequate anterior subdeltoid visualization; if needed, further flexion of the shoulder and elbow may be achieved with elevation of the foot of the table, or one can remove the arm from traction and manually further flex the shoulder and elbow.
 - The neurovascular structures potentially at risk include the musculocutaneous nerve, axillary nerve, and anterior humeral circumflex branches. Careful attention to instrument positioning is vital. During spinal needle placement for retraction of the tendon, one must either tap the needle into bone or slide it just medial to the humerus and stay "on bone" when advancing.
 - Accurate identification of surgical anatomy is paramount. The subscapularis lies just medial to the biceps sheath and may be injured during sheath opening if the biceps tendon and its orientation are not properly identified. Similarly, the upper border of the pectoralis major is an important landmark but must be protected during exposure of the biceps tendon and during tunnel drilling.
 - Excessive tilting of the head away from the surgical shoulder, in combination with a scalene block and traction on the arm, puts the brachial plexus at risk of injury and should be avoided.
-

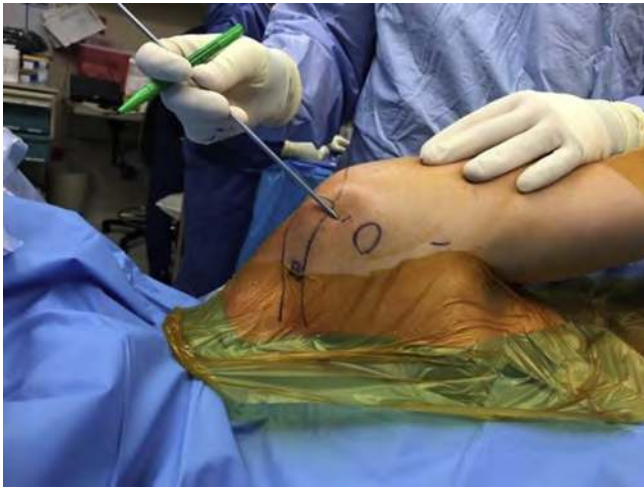

Fig 1. Anterior view of a left shoulder with the switching stick showing the standard anterior-superior portal.

the pectoralis major tendon inferiorly, exposing the biceps tendon. The proximal portion of the transverse humeral ligament is left intact such that the tendon will stay in the groove when traction is applied. The tenosynovium is carefully resected with a shaver along the course of the tendon, and soft tissue is debrided from bone at the proposed tenodesis site. Electrocautery is used as needed to coagulate small vessels to maintain visualization.

A spinal needle is now placed (Fig 10) to localize an anterior-inferior transdeltoid portal allowing a perpendicular trajectory for tunnel drilling. This portal is typically 1 cm superior and 1 cm lateral to the upper fold of the axilla (Fig 11). When the trajectory is confirmed, the same spinal needle is used to retract the

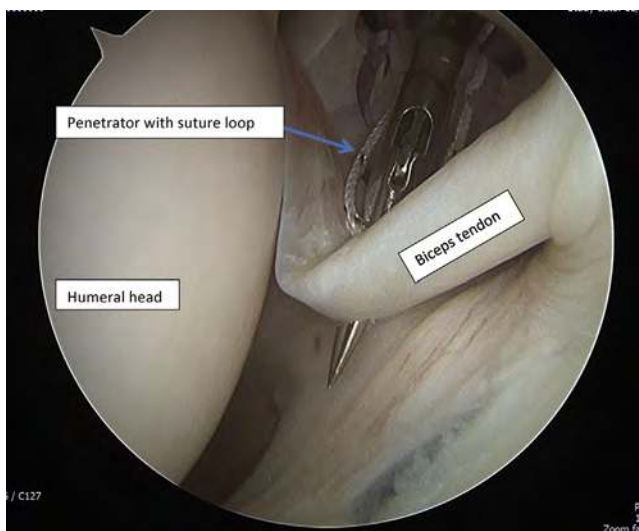


Fig 2. The camera is viewing a left shoulder from the posterior portal. A suture penetrator with a No. 2 suture in a loop configuration is passing through the tendon near the biceps hiatus.

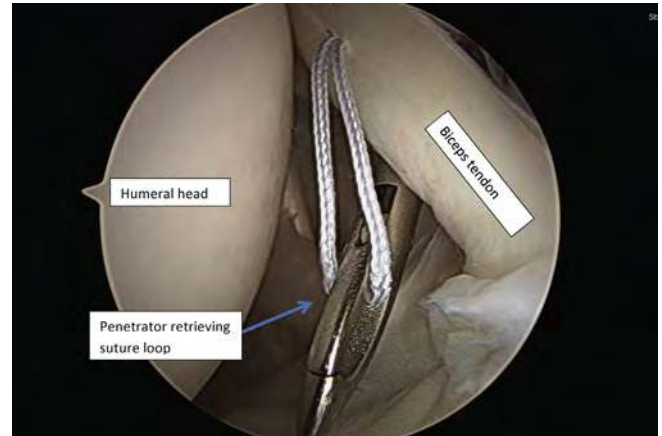


Fig 3. In a left shoulder viewed from the posterior portal, the penetrator is retrieving the suture loop around the tendon.

biceps tendon medially and gently tapped into the bone or slid gently along the medial cortex of the bone, acting as a self-retaining retractor during tunnel drilling (Fig 12). A 2-cm skin incision is then made just far enough lateral to the needle to avoid obstruction between the needle and reamer shaft (usually 1.5 cm). This incision is made through skin only and bluntly dilated with a switching stick, confirming the transdeltoid drilling trajectory (Fig 13). A cannula is not required for this portion of the procedure but may be used if desired.

Reaming of the tunnel is the next step. Generally, an 8.5-mm-diameter tunnel is paired with an 8.0-mm screw for male patients, and an 8.0-mm tunnel is paired with a 7.5-mm screw for female patients; alternatively, an arthroscopic sizer may be used to estimate the tendon diameter. A piloted reamer (Arthrex, Naples, FL) is introduced percutaneously and placed on the humerus 1 to 1.5 cm above the pectoralis tendon,

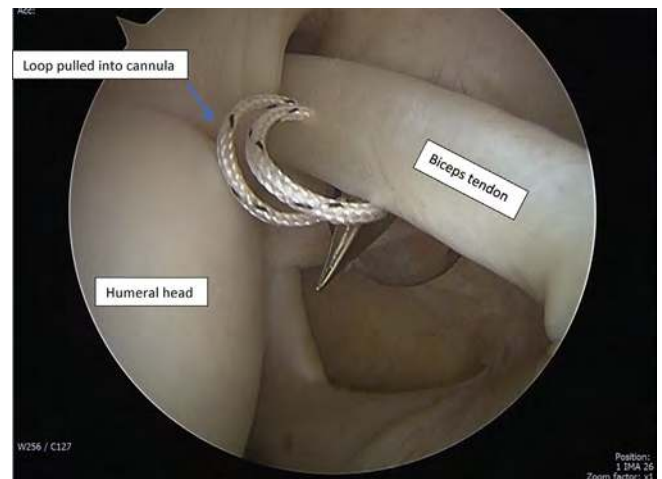


Fig 4. In a left shoulder viewed from the posterior portal, the biceps tendon stay-suture loop is being pulled back up and out of the cannula.

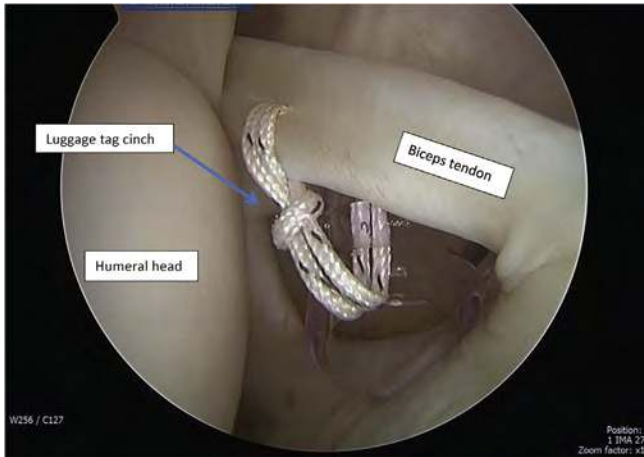


Fig 5. Left shoulder viewed from the posterior portal. The tails of the suture have been passed through the loop outside the cannula and slid back into the joint, creating the luggage-tag (cinch) stitch to control the proximal biceps tendon. One should note that the suture has been placed as close as possible to the biceps hiatus, allowing ample tissue to remain after tenotomy such that the suture will not cut out of the tendon.

and a tunnel is drilled to a depth of 20 mm (Figs 14 and 15). Reaming is stopped at this depth, and the reamer is manually backed out of the tunnel. A shaver and electrocautery are alternately introduced through the same transdeltoid portal to remove bone debris and soft tissue around the tunnel.

Fixation of the tendon into the tunnel is achieved with a bio-composite or PEEK (polyether ether ketone) interference screw with a cleated introducer tip (Arthrex) passed percutaneously through the transdeltoid portal. After the tendon is pulled out to length (Fig 16) with the stay suture, the cleat of the introducer captures the tendon and advances the tendon into the

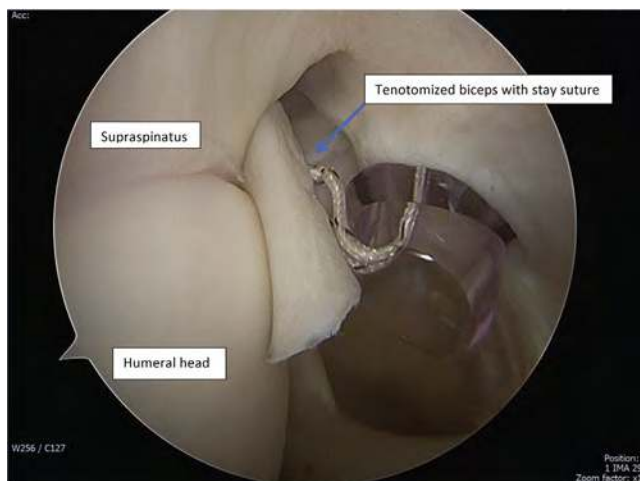


Fig 6. Left shoulder viewed from the posterior portal. The proximal biceps tendon is well controlled after tenotomy with the luggage-tag suture.

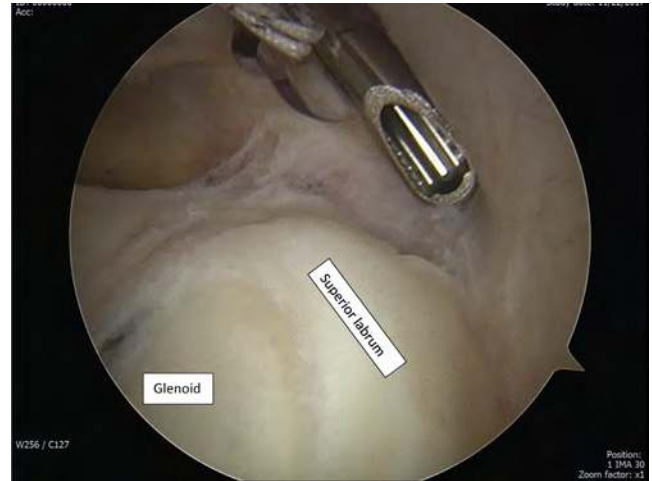


Fig 7. In a left shoulder viewed from the posterior portal, the remaining proximal biceps is debrided back to the superior labrum through the 5-mm cannula.

tunnel (Fig 17). The goal during this step is to prevent over-tensioning. Therefore, as the tip captures the tendon and insertion begins, stay-suture traction is relaxed by the assistant allowing the proximal tendon to slide into the tunnel, whereas the tendon distal to the inserter folds into the tunnel at the inferior aperture, with minimal sliding. Optionally, a spinal needle may be placed into the distal tendon to help stabilize it during insertion. The headed screw is advanced and left 1 to 2 mm proud, allowing the screw threads to remain in cortical bone (Figs 18 and 19). Countersinking may pass the threads past the cortex, destabilizing the screw, and should be avoided. The driver is removed, and the implant stay suture is tested with traction to confirm stability of the screw and then removed. The biceps tendon stay suture is cut and removed proximally, and

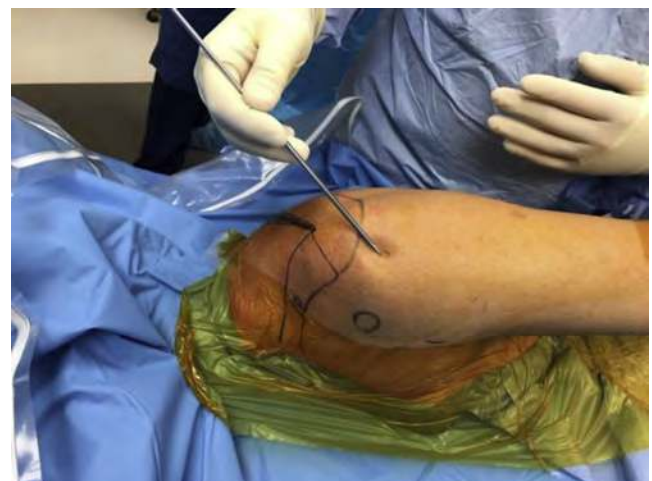

Fig 8. Anterior view of a left shoulder in the lateral decubitus position with the switching stick showing a standard anterolateral working portal.

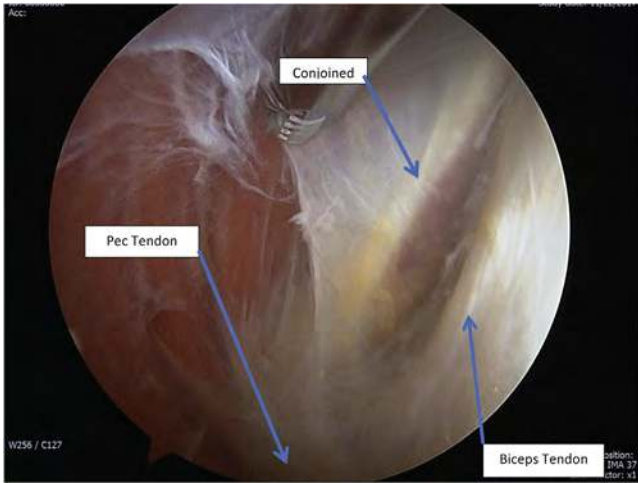


Fig 9. Left shoulder viewed from the anterolateral working portal showing the conjoined tendon in the medial visual field. The pectoralis muscle is seen inferomedially, and the upper border of the pectoralis (Pec) tendon is seen traveling superolaterally to the humerus. The biceps tendon is running vertically, just medial to the pectoralis tendon.

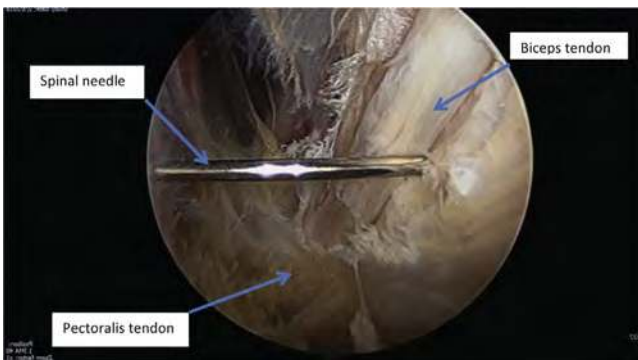


Fig 10. View from the anterolateral portal of a left shoulder with a spinal needle localizing the location and trajectory for tunnel drilling from the anterior-inferior portal location.

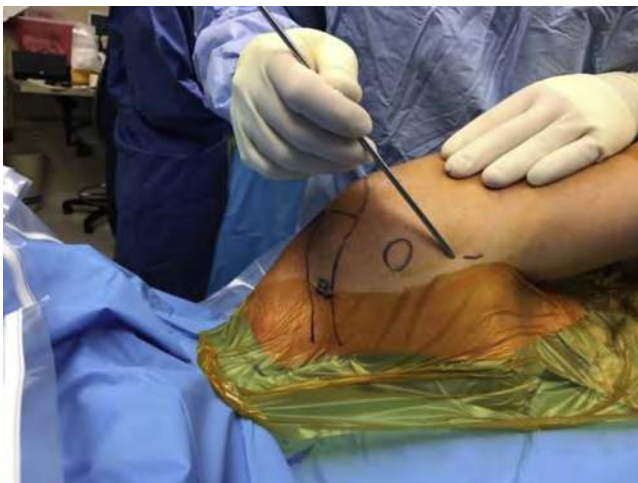


Fig 11. Anterior view of a left shoulder in the lateral decubitus position with the switching stick showing the anterior-inferior transdeltoid portal used for tunnel drilling and placement of the tenodesis screw.

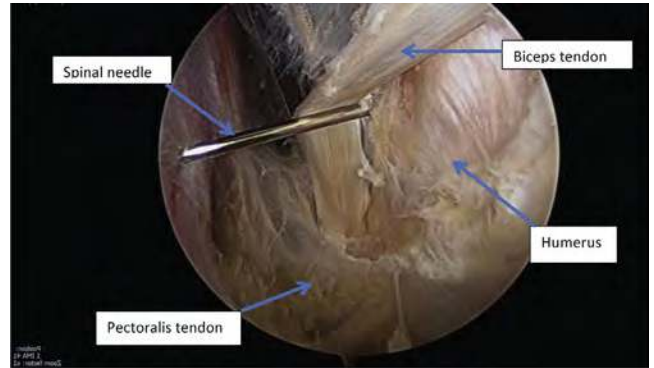


Fig 12. Left shoulder viewed from the anterolateral portal. The spinal needle has retracted the biceps tendon medially and, in this case, slid along the medial humerus to act as a self-retaining retractor, protecting the tendon during drilling. Alternatively, the tip of the needle may be gently tapped into bone with a mallet to hold its position.

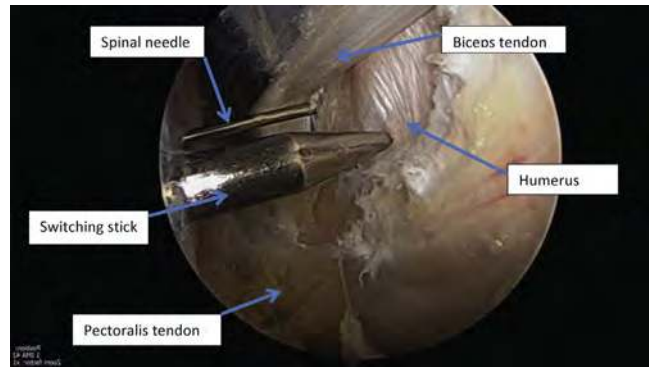


Fig 13. Left shoulder viewed from the anterolateral portal. The anterior-inferior transdeltoid portal has been made just lateral to the spinal needle, and a switching stick is used to dilate the portal and confirm the trajectory for drilling 1 to 1.5 cm above the pectoralis tendon.

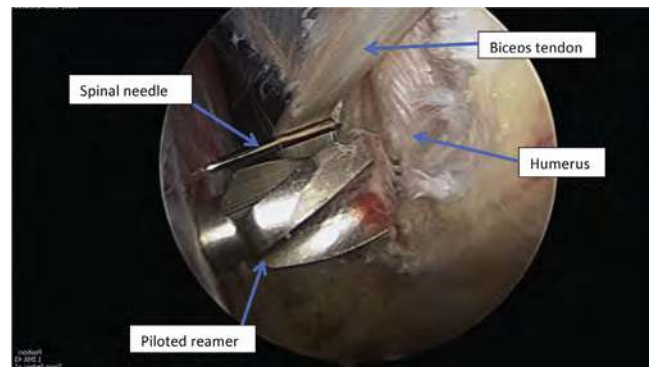


Fig 14. In a left shoulder viewed from the anterolateral portal, a piloted reamer is placed through the anterior-inferior transdeltoid portal for tunnel drilling. The biceps tendon is well protected with the spinal needle in place as a retractor.

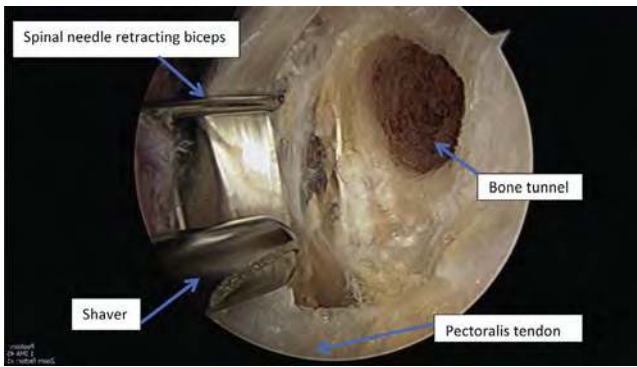


Fig 15. Left shoulder viewed from the anterolateral portal. The tenodesis tunnel is drilled to a depth of 20 mm, and the edges are debrided. The spinal needle is retracted and protects the biceps tendon during drilling.

remaining proximal tendon tissue is debrided with a shaver, completing the procedure. A standard post-operative protocol for biceps tenodesis is begun thereafter with the goal of a return to sporting activity within 3 to 4 months.

Discussion

The role of arthroscopic biceps tenodesis to treat a variety of related shoulder conditions is well established, despite a lack of consensus on the ideal location or method of fixation of the tendon.^{1,4,7} Many surgeons prefer lateral decubitus shoulder arthroscopy and may be less comfortable switching to the beach-chair position for biceps tenodesis, potentially creating a negative impact on surgeon performance of concomitant procedures. The technique outlined in this report is a viable option for surgeons who prefer an arthroscopic supra-pectoral technique and a lateral decubitus position to safely and reproducibly identify and perform tenodesis of the biceps tendon. The patient positioning and viewing portals described in this article routinely provide

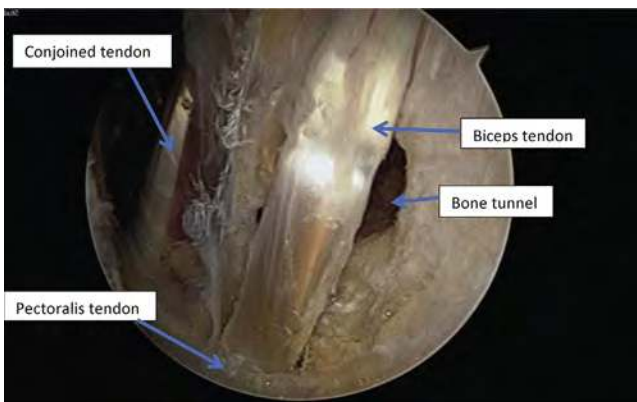


Fig 16. In a left shoulder viewed from the anterolateral portal, the spinal needle is removed and the tendon stay suture is used to pull the tendon out to length. The conjoint tendon is shown nicely in the medial visual field.

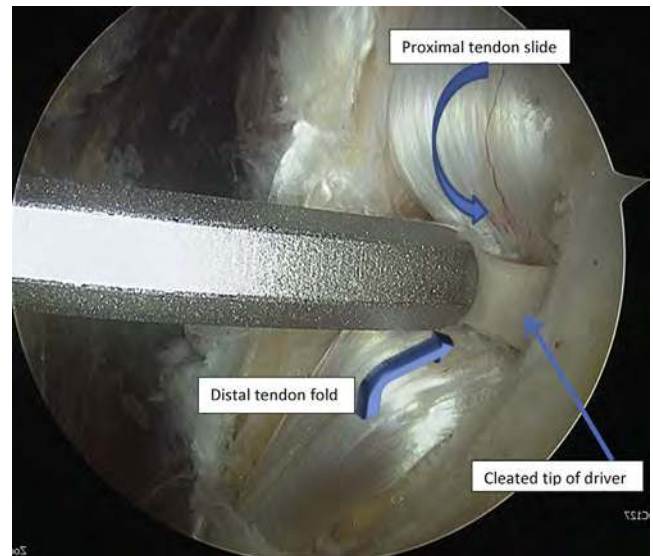


Fig 17. Left shoulder viewed from the anterolateral portal. The cleat of the tenodesis introducer-driver is advancing the tendon into the tunnel. The assistant at this stage will relax tension on the biceps tendon stay suture, allowing the proximal tendon to slide into the tunnel and the distal tendon to fold at the inferior aperture.

excellent visualization of the relevant surgical anatomy (upper border of the pectoralis major and falciform ligament, conjoint tendon, and biceps tendon medial to the pectoralis insertion) to safely proceed with tenodesis. Other descriptions of lateral decubitus tenodesis⁹ have included a superior viewing portal looking “down” the tendon, but we prefer viewing from anterolateral to maintain a consistent orientation. In addition, the moderate to high shoulder and elbow flexion angles described for the beach-chair position^{3,7,8} are useful—but not a requirement—to achieve anatomic visualization of the anterior subdeltoid space, which can

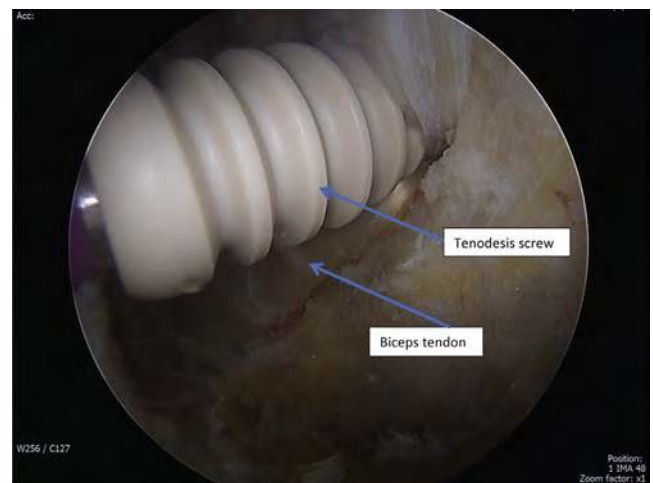


Fig 18. In a left shoulder viewed from the anterolateral portal, the tenodesis screw is advanced into the tunnel.

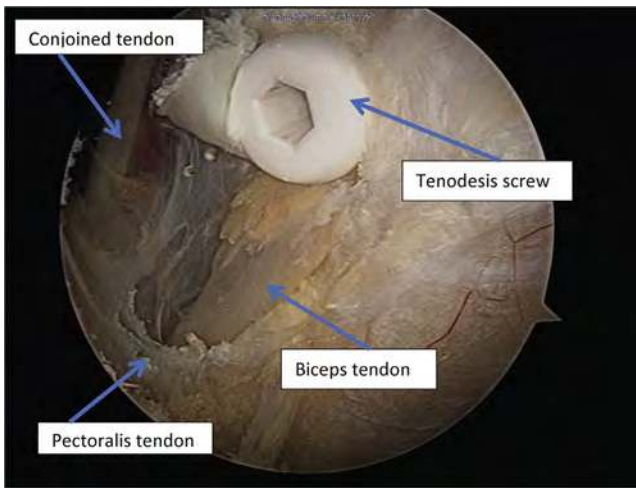


Fig 19. Left shoulder viewed from the anterolateral portal. The headed screw is left 1 to 2 mm proud to maintain threads in cortical bone to secure the construct.

be readily and safely accessed with a lateral decubitus approach.

References

1. Griffin J, Cvetanovich G, Kim J, et al. Biceps tenodesis is a viable option for management of proximal biceps injuries in patients less than 25 years of age. *Arthroscopy* 2019;35:1036-1041.
2. Gombera M, Kahlenberg CA, Nair R, Saltzman MD, Terry MA. All-arthroscopic suprapectoral versus open subpectoral tenodesis of the long head of the biceps brachii. *Am J Sports Med* 2015;43:1077-1083.
3. Hodgins J, Kovacevic D, Purcell S, Jobin C, Levine W, Ahmad C. Arthroscopic suprapectoral and open subpectoral biceps tenodesis: Radiographic characteristics. *Arthroscopy* 2016;32:2234-2242.
4. Werner BC, Evans CL, Holzgrefe RE, et al. Arthroscopic suprapectoral and open subpectoral biceps tenodesis: A comparison of minimum 2-year clinical outcomes. *Am J Sports Med* 2014;42:2583-2590.
5. Green J, Getelman M, Snyder S, Burns J. All-arthroscopic suprapectoral versus open subpectoral tenodesis of the long head of the biceps brachii without the use of interference screws. *Arthroscopy* 2016;33:19-25.
6. Werner B, Lyons M, Evans C, et al. Arthroscopic suprapectoral and open subpectoral biceps tenodesis: A comparison of restoration of length-tension and mechanical strength between techniques. *Arthroscopy* 2014;31:620-627.
7. Nair R, Kahlenberg CA, Patel RM, Knesek M, Terry MA. All-arthroscopic suprapectoral biceps tenodesis. *Arthrosc Tech* 2015;4:e855-e861.
8. Valenti P, Benedetto I, Maqdes A, Lima S, Moraiti C. "Relaxed" biceps proximal tenodesis: An arthroscopic technique with decreased residual tendon tension. *Arthrosc Tech* 2014;3:e639-e641.
9. Tarleton AA, Zhou L, O'Brien MJ, Savoie FH. Arthroscopic biceps tenodesis from a superior viewing portal in the shoulder. *Arthrosc Tech* 2015;4:e383-e389.