

The Role of Hyaluronic Acid Fillers (Restylane) in Facial Cosmetic Surgery: Review and Technical Considerations

Rod J. Rohrich, M.D.
Ashkan Ghavami, M.D.
Melissa A. Crosby, M.D.

Dallas and Houston, Texas; and Los Angeles, Calif.

Background: Bioengineered hyaluronic acid derivatives are currently available that provide for safe and effective soft-tissue augmentation in the comprehensive approach to nonsurgical facial rejuvenation. Current hyaluronic acid fillers do not require preinjection skin testing and produce reproducible, longer-lasting, nonpermanent results compared with other fillers, such as collagen.

Methods: A review of the authors' extensive experience at the University of Texas Southwestern Medical Center was conducted to formulate the salient requirements for successful utilization of hyaluronic acid fillers. Indications, technical refinements, and key components for optimized product administration categorized by anatomical location are described. The efficacy and longevity of results are also discussed.

Results: Bioengineered hyaluronic acid fillers allow for safe and effective augmentation of selected anatomical regions of the face, when properly administered. Combined treatment with botulinum toxin type A can enhance the effects and longevity by as much as 50 percent. Key components to optimal filler administration include proper anatomical evaluation, changing or combining various fillers based on particle size, altering the depth of injection, using different injection techniques, and coadministration of botulinum toxin type A when indicated. Concomitant administration of hyaluronic acid fillers along with surgical methods of facial rejuvenation can serve as a powerful tool in maximizing a comprehensive treatment plan.

Conclusions: Current techniques in nonsurgical facial rejuvenation and shaping with hyaluronic acid fillers are safe, effective, and long-lasting. Combination regimens that include surgical facial rejuvenation techniques and/or coadministration of botulinum toxin type A further optimize results, leading to greater patient satisfaction. (*Plast. Reconstr. Surg.* 120 (Suppl.): 41S, 2007.)

Soft-tissue augmentation with the various soft-tissue filler materials has become one of the most popular aesthetic procedures available to patients who desire nonsurgical facial rejuvenation. The plethora of soft-tissue fillers currently available in the United States today also serves as a powerful adjunct to surgical techniques in facial rejuvenation and facial shaping. The 2003 data from the American Society of

Plastic Surgeons demonstrated a 150 percent increase from 2002 in the use of soft-tissue fillers, with 744,283 procedures performed in this nonsurgical category.^{1,2} Soft-tissue fillers are particularly attractive to younger, middle-aged patients who display minimal to moderate signs of facial aging and who want minimal downtime.

From the Department of Plastic Surgery, University of Texas Southwestern Medical Center; Department of Plastic and Reconstructive Surgery, University of Texas Southwestern Medical School; and Division of Plastic and Reconstructive Surgery, M. D. Anderson Medical Center.

Received for publication January 30, 2006; accepted September 6, 2006.

Copyright ©2007 by the American Society of Plastic Surgeons

DOI: 10.1097/01.prs.0000248794.63898.0f

FDA Status and Approved Uses: Restylane is FDA approved as an injectable gel to treat facial wrinkles. Juvéderm is FDA approved. The three product formulations include Juvéderm 24 HV, a highly cross-linked formulation for more versatility in contouring and volumizing of facial wrinkles and folds; Juvéderm 30 HV dermal filler, a more highly cross-linked

Continued

As the search for an ideal filler material continues, hyaluronic acid derivatives have gained popularity among aesthetic surgeons because of their numerous advantages. An ideal filler material is one that is biocompatible, nonantigenic, nontoxic, easy to use, long-lasting (yet nonpermanent), inexpensive, and reversible. It should demonstrate a high safety profile and produce a predictable result with minimal downtime.

Many of the new fillers available for use in the United States are longer-lasting and have shifted the paradigm between permanent and nonpermanent fillers. Use of permanent or “more permanent” fillers allows less room for error and can produce irreversible changes in facial shape that may not retain the aesthetic changes as the patient ages. With the introduction of hyaluronic acid derivatives for use in soft-tissue augmentation, a safer, longer-lasting, and yet temporary alternative has been made available.

WHAT IS HYALURONIC ACID?

Hyaluronic acid is common among many organisms and is present in connective tissues of skin, cartilage, bone, and synovial fluid. Hyaluronic acid is unique in that it is natively present in the intracellular matrix of the dermis and identical in form in all mammalian species.^{3,4} In human skin, it aids in bulk, lubrication, and shock absorption. Its viscoelastic properties and role in cell membrane protection and stabilization make it a natural choice for dermal soft-tissue augmentation. The amount of hyaluronic acid residing in native tissue decreases with age, leading to reduced dermal hydration and increased folding.^{5,6}

Hyaluronic acid is a glycosaminoglycan biopolymer of alternating D-glucuronic acid and N-acetyl-D-glucosamine monosaccharide residues cross-linked into long, repeated, unbranched polyanionic chains. The repeating chains are hydrated and coil

upon themselves, providing the substance with elasticity and viscosity. Hyaluronic acid acts by binding water molecules, which leads to increased skin hydration and turgor. Its hydrophilic properties help the product maintain its volume and viscoelasticity when it is injected.

Exogenous hyaluronic acid is rapidly eliminated by lymphatics and degraded in the liver to carbon dioxide and water.⁵ Without cross-linking, the tissue half-life is only 1 to 2 days. Manufacturers, therefore, have had to modify the physical and chemical properties to allow long-lasting results.

The goal of bioengineered hyaluronic acid is to improve its stabilization via increased tissue residency, viscosity, and elasticity while preserving its innate biocompatibility. The bioengineered hyaluronic acid derivative is chemically cross-linked, which alters its solubility and rheological profile so that it becomes a more viscous, water-insoluble gel. This process has dramatically improved its stability when it is injected into tissue. The hyaluronic acid gel properties are, therefore, controlled by varying the molecular weight, concentration, and degree of cross-linking. This process helps retain the biological compatibility of the native polymer, slow its dissolution rate, and increase its residence time when it is injected into dermis.⁷⁻¹²

Hyaluronic acid derivatives first received Food and Drug Administration approval in the United States for soft-tissue augmentation in December of 2003 with the introduction of Restylane (Medicis Aesthetics, Inc., Scottsdale, Ariz.) followed by Hylaform (Inamed, Santa Barbara, Calif.) in April of 2004, Hylaform Plus in October of 2004, and Captique (Allergan, Santa Barbara, Calif.) in December of 2004.¹³⁻¹⁵ The majority of the long-term experience with these filler products can be found in both the European and Canadian literature, with up to 9 years of experience in more than one million patients. The hyaluronic acid derivatives available in these countries include Hylaform Gel, Hylan Rofilan Gel, Achyal, Restylane, Restylane Fine Lines, and Perlane.¹⁶ These various hyaluronic acid derivatives differ in particle size, molecular weight, and degree of cross-linking, making each optimal for injection into specific dermal layers and facial regions (Table 1).

For example, Restylane Fine Lines is a lower-density, less viscous filler that is indicated for the more superficial dermis (dermoepidermal junction), whereas Restylane is composed of medium-density particles, more viscous, and better suited for augmentation of the mid-dermis. Perlane is a high-density, longer-lasting hyaluronic acid filler

robust formulation for volumizing and correction of deeper folds and wrinkles; and Juvéderm 30, a highly cross-linked formulation for subtle correction of facial wrinkles and folds. Captique is approved for injection into the mid- to deep dermis for correction of moderate to severe facial wrinkles. Hylaform is approved for injection into the mid- to deep dermis for correction of moderate to severe facial wrinkles and folds (such as nasolabial folds).

Table 1. Characteristics of Various Hyaluronic Acid Fillers

	Restylane	Hylaform	Hylaform Plus	Captique
Cross-linking agent	BDDE	DVS	DVS	DVS
HA concentration	20 mg/ml	5.5 mg/ml	5.5 mg/ml	5.5 mg/ml
Particle size	250 μ m	500 μ m	750 μ m	500 μ m

BDDE, 1,4-butanediol diglycidylether; DVS, divinyl sulfone; HA, hyaluronic acid.

that is very useful for deep dermal injection. Perlane is currently the largest hyaluronic acid compound available. Perlane is an effective, long-lasting filler indicated for augmentation of the deeper dermal level. However, thicker hyaluronic acid fillers (i.e., larger particle size) can be less forgiving in more superficial dermal layers and can produce lumpiness and more erythema if caution is not used.

COMMERCIALLY AVAILABLE HYALURONIC ACID PRODUCTS (UNITED STATES)

Restylane

Restylane is a partially cross-linked hyaluronic acid derivative obtained from a bacterial (*Streptococcus*) fermentation process that forms a viscoelastic, transparent gel. Because it is a non-animal-derived compound, there is no risk of transmitting diseases and minimal risk of allergic reactions, so the need for preinjection skin testing is eliminated. As with other bioengineered hyaluronic acid derivatives, Restylane binds water with great affinity and can maintain its bulk as it undergoes “isovolemic degradation.” This stability is provided by the high degree of cross-linking, which allows for its long-lasting effect (up to 4 to 6 months, depending on the location and injection technique).¹⁷ Restylane is indicated for mid- to deep dermal implantation for moderate to severe facial wrinkles and folds/nasolabial folds.^{14,17} Restylane is provided in 0.4-ml and 1.0-ml preloaded, 30-gauge, 1.5-inch-long needle syringes containing 20 mg/ml of stabilized hyaluronic acid.^{18,19} The product syringes have a shelf life of 1.5 years.

Hylaform/Hylaform Plus

Hylaform and Hylaform Plus, both hyaluronic acids derived from avian proteins, were approved by the Food and Drug Administration in April and October of 2004, respectively.¹⁵ These products are indicated for injection into the mid- to deep dermis for correction of moderate to severe facial wrinkles and folds. Both products are supplied in individual treatment syringes, with 30-gauge needles packaged for single-patient use and ready for injection. Each syringe contains a solution of hy-

lan B gel (5.5 mg/ml), sodium chloride (8.5 mg/ml), and water. Hylaform Plus has a larger particle size compared with Hylaform.^{15,20–22} As with other hyaluronic acid derivatives, no skin testing is required.

Juvéderm

Juvéderm (Allergan, Inc., Irvine, Calif.) was approved by the Food and Drug Administration in June of 2006 for use as a dermal filler. The makers of Juvéderm consider it to be “next generation” hyaluronic acid–based dermal filler.²² It possesses all the benefits of a hyaluronic acid–based filler and reportedly comes in a smooth gel form that is different from other hyaluronic acid fillers that use particle suspension technology.²² In addition, the manufacturer states that it contains the highest concentration of nonanimal and cross-linked hyaluronic acid currently available.²² There are three formulations available: Juvéderm 24 HV, a highly cross-linked formulation; Juvéderm 30 HV dermal filler, a more highly cross-linked robust formulation intended for deeper filling; and Juvéderm 30, for more shallow and superficial dermal augmentation.

Captique

Captique is a newer hyaluronic acid derivative, manufactured and packaged in the same manner as Hylaform. It was approved by the Food and Drug Administration in December of 2004 based largely on the approval of Hylaform. Captique differs from Hylaform in that it is derived from a bacterial source rather than an avian source. Captique is indicated for injection into the mid- to deep dermis for correction of moderate to severe facial wrinkles.^{13,22}

EFFICACY

The efficacy of hyaluronic acid fillers has been demonstrated in numerous clinical trials. Olenius¹⁶ found in his series of 100 patients treated with Restylane that 60 percent of the effect was present at the 12-month follow-up. In a prospective, randomized, controlled study using a non-animal-sourced hyaluronic acid [or NASHA (Restylane)] in combination with botulinum toxin type A (Botox; Allergan,

Irvine, Calif.), Carruthers and Carruthers²³ demonstrated an improved and longer-lasting aesthetic response for glabellar rhytides when Restylane was used in combination with Botox. At a follow-up of 16 weeks, 83 percent of the Restylane group, compared with 95 percent of the Botox/Restylane group, had aesthetic improvement.²³ This finding may be explained by the reduction in dynamic muscle action that could reduce filler deformation within the dermis. In addition, the subjects in the study commented on more “instantaneous” results when Restylane was added to Botox treatment for severe glabellar folds.²³

In a pivotal one-to-one randomized, double-blind, multicenter trial, Narins et al.¹⁷ compared the efficacy of Zyplast [bovine collagen (Allergan, Santa Barbara, Calif.)] to that of Restylane in the treatment of nasolabial folds. Using a Wrinkle Severity Rating Scale and a Global Aesthetic Improvement Scale, the authors found that Restylane required less volume and fewer treatments to achieve an “optimal cosmetic result,” as evaluated by blinded investigators.¹⁶ In addition, both Restylane and Zyplast demonstrated a similar safety profile.¹⁶

The pivotal trial for Hylaform compared the safety and efficacy of Hylaform viscoelastic gel with those of Zyplast for the correction of nasolabial folds in a prospective, multicenter, randomized, double-blind, parallel-group study conducted during an initial 12-week treatment phase.^{15,20} Hylaform gel was found by an independent review of photographs to be equivalent to Zyplast (control filler) in the correction of nasolabial folds.²⁰ As of this writing, there have been no clinical trials involving the use of Captique; Food and Drug Administration approval of this product was based on trials involving other hyaluronic acid fillers.¹³

LONGEVITY

One significant advantage of hyaluronic fillers over more traditional nonpermanent fillers, such as fat and collagen, is their increased tissue longevity (Table 2). In our clinical experience, the

Table 2. Longevity of Hyaluronic Acid

Treatment Area	Longevity
Lips	3–4 months
Nasolabial fold	4–6 months
Tear trough	>6 months
Glabellar and forehead region	6 months (up to 9 months with Botox*)
Oral commissures	3–4 months

*Efficacy is enhanced by up to 50 percent in the lip, glabellar, forehead, and oral commissure areas with coadministration of Botox.

purported longevity of 6 months has not been seen in all areas of injection. In the tear trough, malar, and glabellar regions, the longest longevity we have seen has been approximately 6 months. This has been enhanced to as long as 9 months with concomitant Botox treatment in the glabellar and forehead regions. In the nasolabial fold, adjunctive injections are usually necessary within 4 to 6 months and are required less often as injection sessions proceed. A layering technique in this area can also prolong injection intervals. The shortest duration, of approximately 3 to 4 months, has been seen in the lip region in our patients, chiefly in long-lip patients with minimal initial bulk. Before injection, all patients are informed of the inherent variability in duration of effect; this is a critical part of the informed consent process. Re-injections (not including touch-ups) of specific areas are usually performed 4 to 6 months after the initial injection. In our experience, an additive effect is evident as the number of injections increases. Often, progressively less product volume is required with each subsequent injection.

INDICATIONS

With aging, the skin loses its viscoelasticity, which is maintained in part through the innate properties of hyaluronic acid. Volume loss, especially in the lips, nasolabial, and malar regions, is seen with advanced age. Useful, more objective methods of rating the severity of facial rhytides and the corrective results have been described by Fitzpatrick et al.,²⁴ Glogau,²⁵ and Lemperle et al.²⁶ Lemperle et al.²⁶ developed a 0- to 5-point rating scale to assess results after soft-tissue augmentation with fillers (Table 3).

Table 3. Classification of Facial Wrinkles*

Grade	Description	Areas Assessed
0	No wrinkles	Horizontal forehead lines
1	Just perceptible wrinkle	Glabellar frown lines
2	Shallow wrinkles	Periorbital lines
3	Moderately deep wrinkle	Preauricular lines
4	Deep wrinkle, well-defined edges	Cheek lines
5	Very deep wrinkle, redundant fold	Nasolabial folds Radial upper lip lines Radial lower lip lines Marionette lines Labiomental crease

*Adapted from Lemperle, G., Holmes, R. E., Cohen, S. R., and Lemperle, S. M. A classification of facial wrinkles. *Plast. Reconstr. Surg.* 108: 1735, 2001.

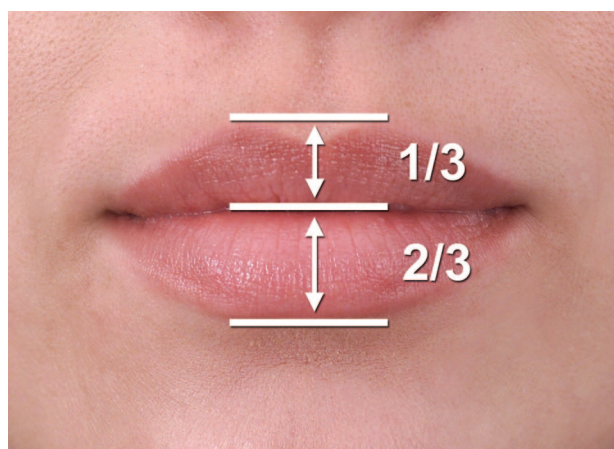


Fig. 1. Aesthetic upper-to-lower lip height balance. The upper lip is approximately one-third of the height and the lower lip is two-thirds of the total lip height. This corresponds to the relative volume differences between the upper and lower lips.

The lips and perioral region are the central aesthetic component of the lower third of the face. Lips express emotion, sensuality, and vitality. In evaluating the aesthetic lip, it is critical to assess the surrounding soft tissues as well as the maxillofacial harmony (Fig. 1). Some of the characteristics of an aesthetic and youthful lip are listed in Table 4 and shown in Figures 1 through 5. With aging, the lips undergo changes in vermilion bulk (pout) and exposure (thin lips) that can be exaggerated by bony retrusion and changes in dentition (Fig. 4). Patients who require subtle refinements in lip fullness, projection, and degree of eversion are ideal candidates for augmentation with hyaluronic acid fillers (Fig. 5). In addition,

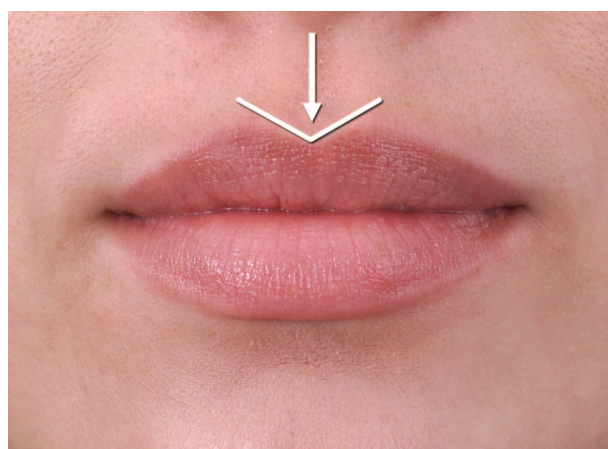


Fig. 2. The Cupid's bow is sharp and well defined in youthful lips.

marionette lines, the deep mental groove, and the anterior jowl line must also be evaluated and augmented when indicated, to optimize overall lip and perioral aesthetics.

With increasing nasolabial fold depths, the face appears older and lacking in midface support. Hyaluronic acid fillers are ideal for blunting prominent nasolabial folds. Malar atrophy, resulting from fat, muscle, and skeletal atrophy, and soft-tissue descent contribute to the aging appearance of the middle third of the face (Fig. 6). Combining both surgical and nonsurgical options to provide support and fullness to the midface can result in marked rejuvenation in this facial region. It is not uncommon to perform a face lift and inject hyaluronic acid filler into the lips, nasolabial folds, and malar or nasojugal areas. Hyaluronic acid aug-

Table 4. Comparative Features of the Youthful/Aesthetic Lip and the Aging Lip

Aesthetic Lip	Aging Lip
One-third upper to two-thirds lower lip height ratio	Upper and lower lips equal out, thin, and stretch out
Distinct Cupid's bow	Loss of Cupid's bow
Central fullness of the upper lip	Thin, uniform, contoured upper lip
Concave sloping of the upper and lower lips	Convex, ill-defined sloping projection from the nasal base and labiomental groove
Upper lip 1–2 mm anterior to the lower lip	Equalized projection of the lips
Vermilio-cutaneous borders thickened with a pout	Loss of vermilio-cutaneous pout
Philtral columns prominent and full	Philtral columns flattened
Commissures slightly upturned	Commissures downturned

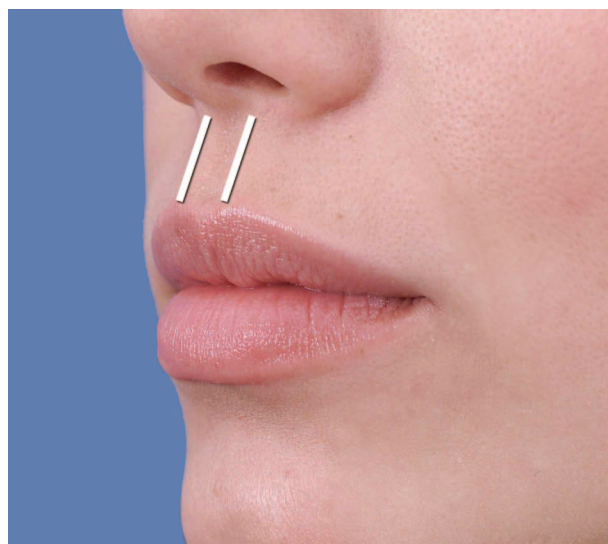


Fig. 3. Youthful lips have full philtral columns that add upper lip-to-nasal base fullness.

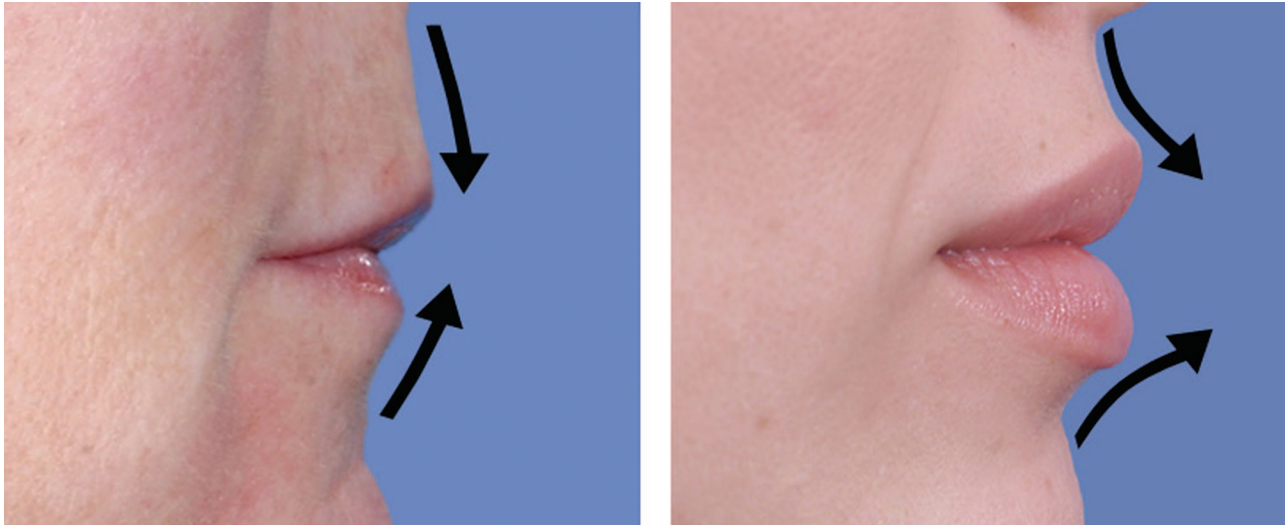


Fig. 4. (Left) Aged lips with ill-defined and convex upper and lower lip sloping. (Right) Youthful lips demonstrate gentle concave sloping from the nasal base and labiomental groove. This provides the lips with a pleasing “pouty” appearance.

mentation can be beneficial for rejuvenation of numerous regions of the face (Table 5).

Combining fillers with Botox adds to the harmonious facial aesthetic balance. The amplified aesthetic result was shown by Carruthers and Carruthers,²³ as discussed above. In our opinion, optimum efficacy is achieved by coinjection of Botox in numerous facial regions when indicated, including the brow/lateral canthal area, depressor angular oris, and glabella (Fig. 7). Hyaluronic acid can then be used to fill the nasolabial and deep glabellar folds, augment the lips, and blunt the tear trough (Fig. 1). In our experience, using Botox to relax the upper face and hyaluronic acid fillers to fill the lower face has provided our pa-

tients with an excellent aesthetic result that is further enhanced by up to 50 percent (Table 2).

TECHNIQUE

Annually, the senior author (R.J.R.) injects more than 350 patients with hyaluronic acid fillers at University of Texas Southwestern Medical Center. The majority of experience has been with Restylane alone or in combination with Botox. Satisfactory injections require a thorough understanding of the product’s potential and the patient’s expectations. Product knowledge includes proper technique, preparation, and training for the physician and office staff, as well as an understanding of the product’s characteristics and guidelines. Patient knowledge includes expectations, prior experience with injected filler material(s), and perceived downtime. Close patient follow-up is paramount to successful incorporation of fillers into one’s practice. In the senior author’s practice, all patients are seen at 2 weeks after injection to ensure treatment success. Touch-up injections at this time are needed in less than 5 percent of patients, and the next visit is scheduled at 3 to 4 months. Regular follow-up allows for lower filler volume requirements with subsequent visits, especially in the perioral and nasolabial fold regions.

The depth of hyaluronic acid injection is a critical consideration in optimizing the aesthetic result. Hyaluronic acid fillers with smaller gel particles are best suited for injection into the superficial or upper part of the dermis. These fillers are

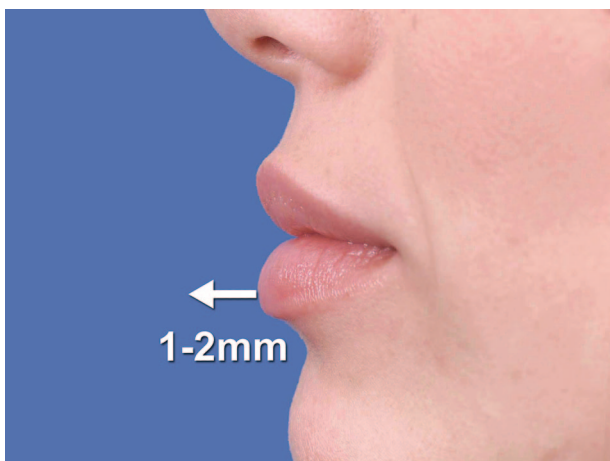


Fig. 5. The upper lip should project 1 to 2 mm anterior to the lower lip.

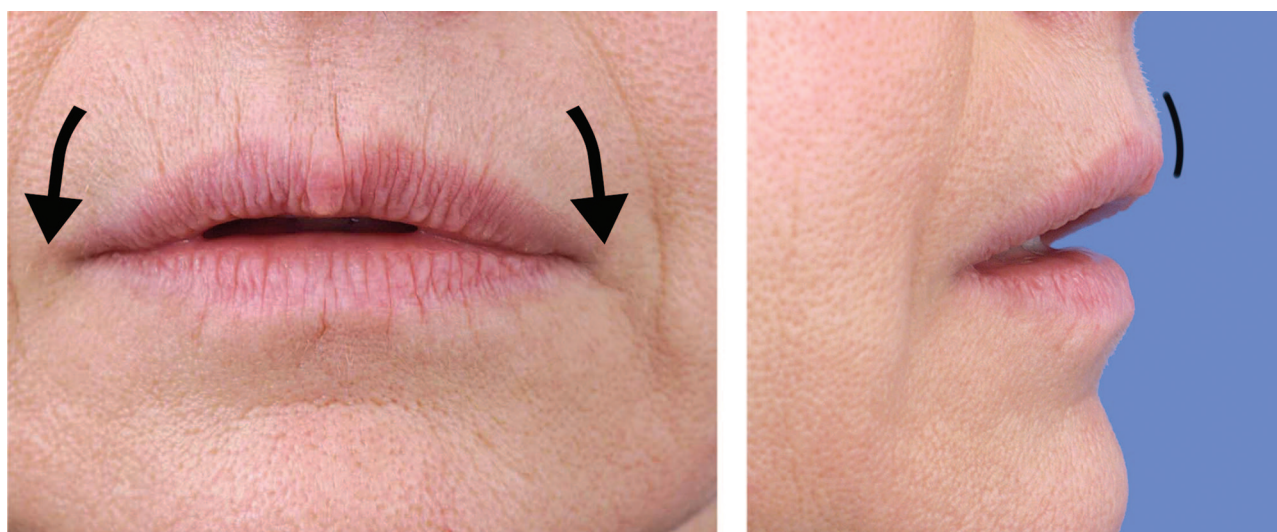

Fig. 6. (Left) Descent of the oral commissures is seen with aging. (Right) Commissure downturning is also seen on the lateral view, along with flattened upper lip sloping.

used to correct superficial lines, such as forehead (“worry” lines), periorbital, and perioral (vertical) rhytides. More moderate facial areas, such as glabellar and forehead lines, nasolabial folds, and atrophic scars, are best augmented in the mid-dermis level with hyaluronic acid fillers with medium-sized gel particles. Layering the filler(s) at different depths can further improve the final contour and efficacy.

Before injection, informed consent is obtained from the patient. The majority of patients receive a combination of topical, local, and regional anesthesia. Topical anesthetic creams include benzocaine, lidocaine, and tetracaine (New England Compound, Farmingham, Mass.) and are applied 20 minutes before injection of local anesthesia. Regional anesthesia includes infraorbital and mental nerve blocks with 1% lidocaine and 1:200,000 epinephrine, or septocaine, which we have found to produce less discomfort and stinging. Supplemental, low-volume local anes-

thetic is given in the perioral area, with an average requirement of 1.5 cc of 0.5% lidocaine per side with 1:200,000 epinephrine, buffered with 0.5 cc of bicarbonate, and injected via a 30-gauge needle. In our experience, this does not distort the treatment area.

The following are guidelines for injection into specific facial regions based on our institutional experience. As mentioned earlier, injection around the nose and mouth is approved by the Food and Drug Administration. All other areas of injection are considered off-label use.

INJECTION TECHNIQUES

Various injection techniques have been described. Familiarity with all of these techniques is

Table 5. Potential Treatment Areas for Hyaluronic Acid Filler Injection

Primary Treatment Area	Injection Site
Lips*	Mental groove
Nasolabial folds	Infraorbital and supraorbital hollows
Glabellar lines	Soft acne or other scars
Marionette lines	Temporal hollow
Nasojugal fold (“tear trough”)	Malar region
Forehead lines	Philtral columns

*“Lips” includes the vermilio-cutaneous border, volume enhancement, and vertical rhytides.

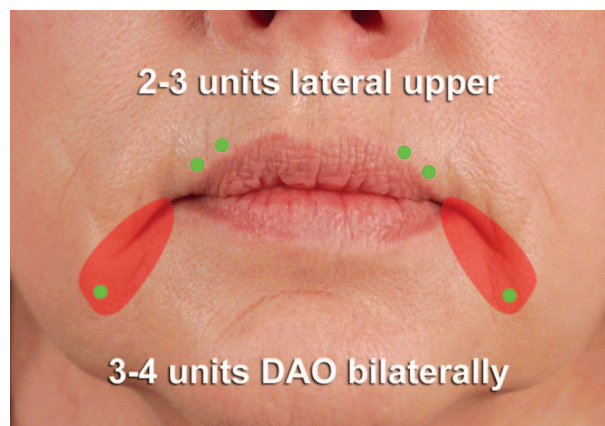

Fig. 7. Botox injected into the upper lip orbicularis oris and depressor anguli oris (DAO) muscles is combined with Restylane soft-tissue augmentation to enhance efficacy.

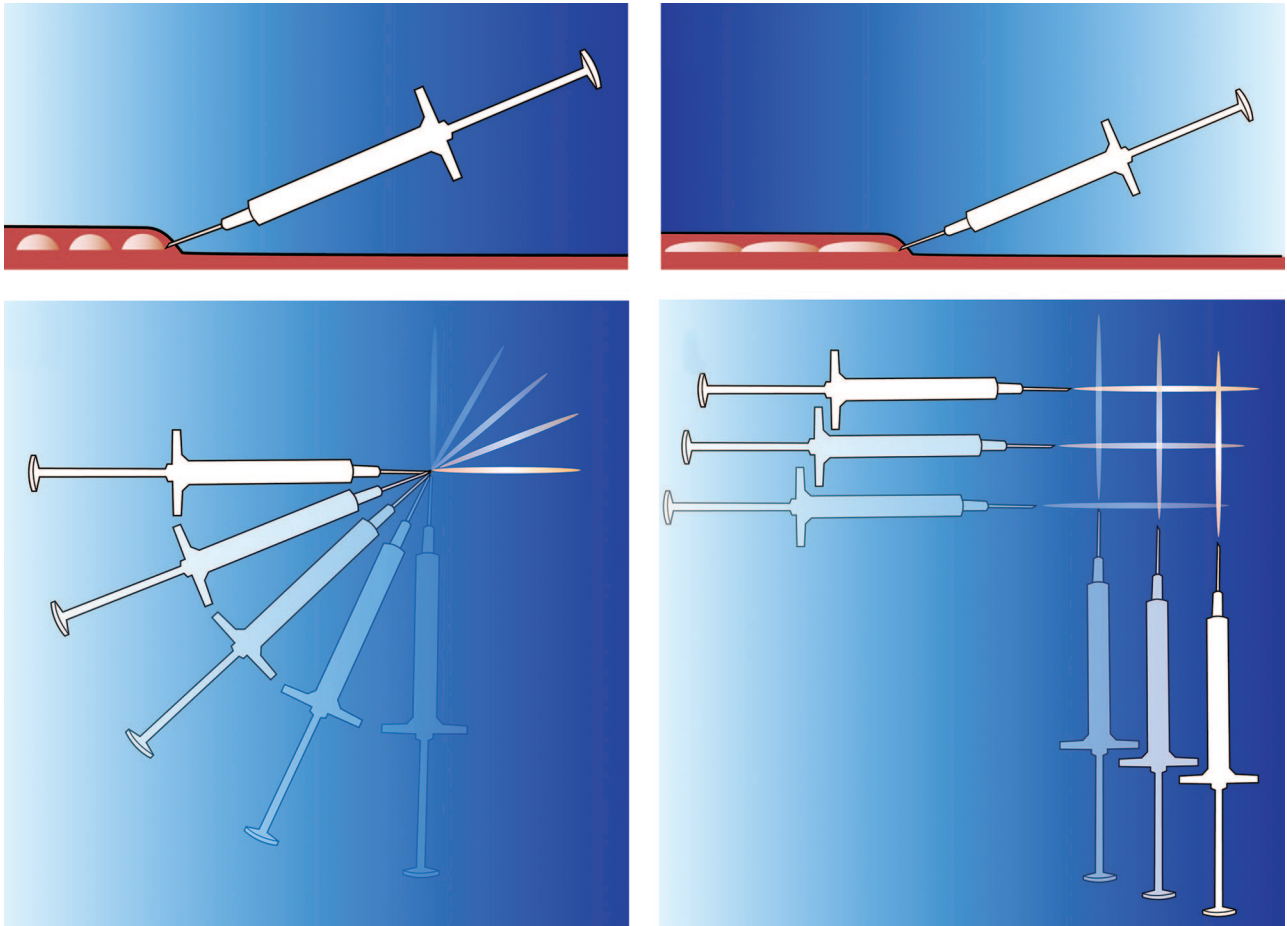


Fig. 8. (Above, left) Serial puncture. (Above, right) Linear threading. (Below, left) Fanning. (Below, right) Cross-radial (cross-hatching).

vital to improving efficacy and aesthetic results (Fig. 8).

Serial Puncture

Serial puncture is optimal for the glabella, for philtral column enhancement, and for fine rhytides. It can also be used for the nasolabial folds. Multiple injections are made serially along the fine wrinkle or fold. The injection sites should be close together, so that the injected material merges into a smooth, continuous line that ultimately lifts the wrinkle or fold. It is helpful to pull the skin slightly away and out from the injection area while injecting. No spaces should remain between the serially injected material. If some minimal gaps are present, postinjection molding and massage can be used to blend the material into a smooth layer.

Linear Threading

The vermilio-cutaneous border and nasolabial folds are best treated using linear threading. The full length of the needle is inserted into the mid-

dle of the wrinkle or fold to create a channel. The product is usually injected while the needle is slowly pushed forward, so that “threads” are deposited along the length of the wrinkle or fold. One can inject while advancing the needle, which may push blood vessels out of the way, or one can utilize a retrograde injection technique, inserting product while withdrawing the needle from the tissue. Which approach to use is largely the preference of the surgeon.

Fanning

We have not found fanning to be particularly useful. The needle is inserted in a fashion similar to that used in the linear threading technique, but immediately before the needle is withdrawn, its direction is changed and a new line is injected (without withdrawing the needle tip from the skin). The fanning pattern of lines should be evenly spaced in a progressive clockwise or counterclockwise direction, so that the contour is evenly filled and shaped. This technique is best suited for deep malar injection.

Cross-Hatching (Cross-Radial)

Cross-hatching is especially effective for filling the oral commissures. The needle is inserted in a fashion similar to that used in the linear threading technique, but before beginning the procedure, the cross-hatching lines should be carefully demarcated. A series of linear threading injections is made in the treatment region. The pattern of lines should be evenly spaced in a progressive grid so that the contour is evenly filled and shaped. This technique is used when a relatively large area requires correction (i.e., facial contours) to maximize filler coverage of the treatment area. This technique is particularly useful for the perioral area.

TECHNIQUE REFINEMENTS

Lips

As with all aesthetic procedures, accurate and comprehensive aesthetic analysis is the first step (see above). Any asymmetries, previous injection sites, irregularities, and scars should be noted and pointed out to the patient and improved upon if feasible. Hyaluronic acid fillers are more viscous than collagen material, and injection may be more difficult until familiarity with the product is attained. While materials with smaller particle sizes, such as Restylane Fine Lines, flow more easily from the syringe and demonstrate less tissue resistance when injected in the proper plane, it is still imperative to release the material from the syringe in a smooth and even fashion to avoid lumping and surface irregularities.

Optimal lip rejuvenation involves two main components: volume enhancement and vermilio-cutaneous border enhancement. Volume filling is often required in older patients and those who have thin lips. Vermilio-cutaneous enhancement is usually required in younger individuals who have enough volume, but it is also indicated in older patients, along with volume augmentation.

Linear threading and/or serial puncture techniques are implemented starting at the oral commissures and proceeding in a lateral to medial direction. Marionette lines are a key element in overall lip enhancement; otherwise, results are destined to be disappointing to both the patient and the physician. A cross-radial technique is used around the oral commissure and marionette line to enhance and “lift,” or fill in, the corners of the mouth. Botox injection into the depressor anguli oris can further enhance this lifting effect. The dermal level is, once again, the mid-dermis. A range of 0.5 to 1.5 cc is often needed for each lip.

Care should be taken to avoid superficial injection in this region, as a light blue hue may become visible. Intrainjection and postinjection palpation for surface irregularities is important. If material tracks away from the intended injection plane and created tunnel, then immediate massage is necessary to recontour the area. Massaging should be instituted immediately by the physician, as this is the best time to achieve molding and shaping. This avoids later discomfort that can be present if the patient is given that task.

Injection of the lip itself can be accomplished at the submucosal level, within the superficial orbicularis oris muscle mass. Placing the hyaluronic acid in this deeper level decreases its visibility and augments lip volume. Minimal augmentation of the philtral columns can further enrich the periorbital and lip augmentation. Restylane can also be used to refine the white rolls, which will enhance the overall aesthetic result. More superficial, finer vertical rhytides are augmented with smaller-particle hyaluronic acid (Restylane Fine Line) or collagen. Concomitant injection of 2 to 4 U of Botox will further improve the longevity of lip rejuvenation by as much as 50 percent.

The final result of overall lip rejuvenation should be evident immediately after the injections, unless excess bruising and edema are present (Fig. 9). Immediate swelling is uncommon and may be a result of histamine release or immediate particle expansion by water absorption. Bruising, if present, should be controlled with compression during the injection so that there is no compromise of the final result from blood staining or volume due to extravasated blood.

Nasolabial Fold

An assessment of the depth and character of the nasolabial fold is critical to a successful outcome. Lemperle et al.²⁶ provide a useful classification system for grading nasolabial fold depth. A concomitant face lift will also affect the degree to which the fold will require soft-tissue filler augmentation (blunting). The fold will never fully correct, and this would be unnatural even if it were possible. Nevertheless, a 50 percent or more correction is attainable with proper technique and patient selection. Soft-tissue augmentation of a deep fold can be a powerful tool when combined with a midface or face lift technique that also addresses the nasolabial region.

A combination of serial puncture and linear threading in the mid- to deeper dermis is used in this region, while the nasolabial fold is held taut.

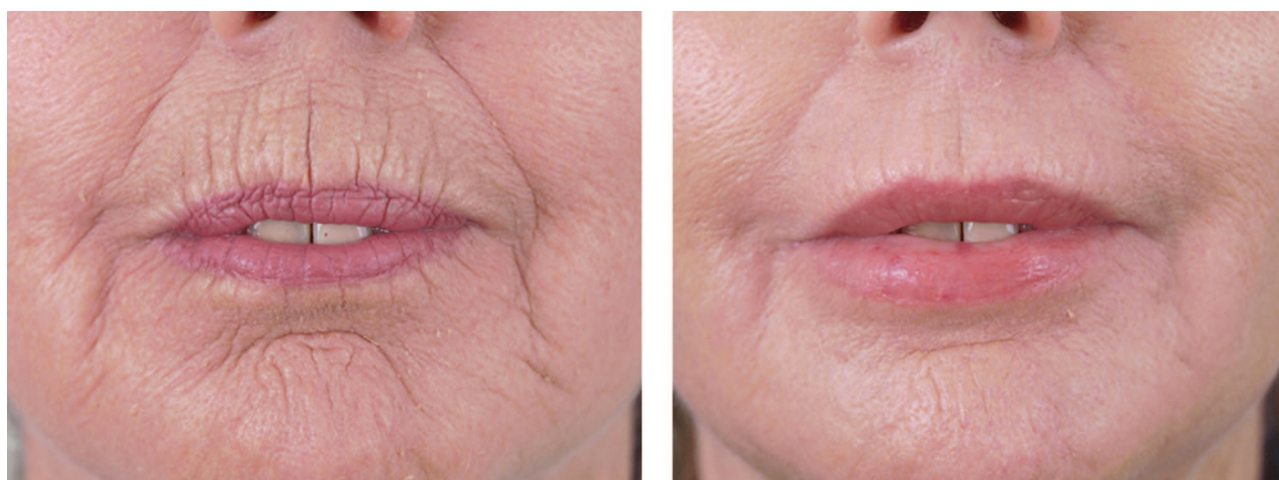

Fig. 9. Before and 4-month follow-up after administration of 3 cc of Restylane (1.5 cc at the vermilio-cutaneous border and lip rhytides and 1.5 cc to the nasolabial folds bilaterally) and an adjunctive 35 percent moderate-depth trichloroacetic acid chemical peel.

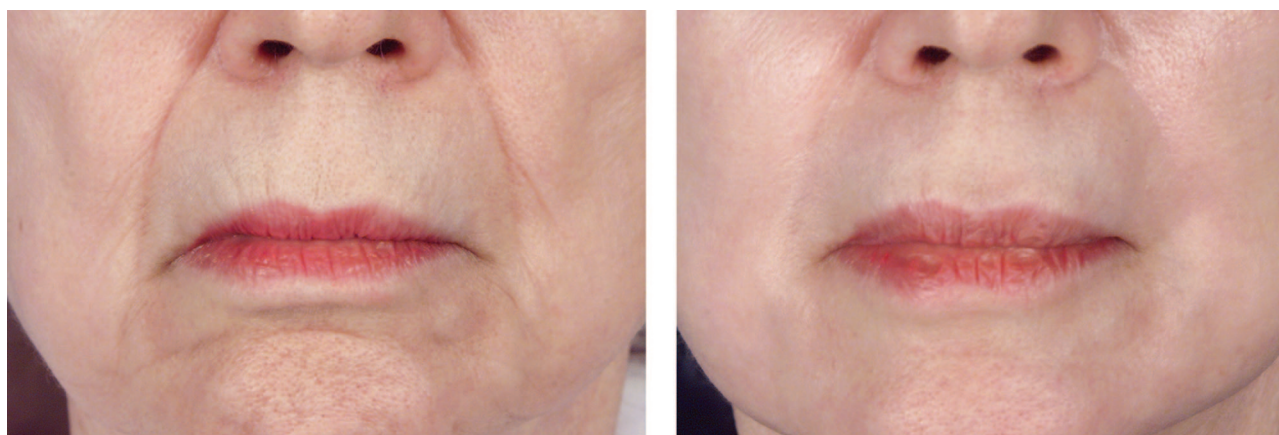


Fig. 10. Before and 6 months after 2 cc of Restylane was added to the vermilio-cutaneous border and marionette lines.

Serial puncture injections should be aimed medially away from the large cheek fold, beginning inferiorly and moving superiorly. The dermis is often thicker as one moves superiorly. Beveling the needle up assists with etched-in lines, as does injection of smaller-particle hyaluronic acid in a layered fashion. Molding of the hyaluronic acid by immediately massaging it will help soften and smooth out the blunted fold. Overcorrection can result in an awkward, paradoxically aged appearance when smiling, as a softness in the upper one-third of the nasolabial fold is natural and youthful (Fig. 10).

Approximately 0.5 to 2.0 cc is used per patient for the nasolabial region. As stated above, complete fold correction is not desirable, is difficult to attain, and should not be the goal in this region (Fig. 11). Subsequent touch-up layering or further

blunting of fold depth can be accomplished at follow-up visits.

Glabellar Folds

Optimal treatment of the glabellar region often requires combined treatment with both hyaluronic acid and Botox (Fig. 12). This combined treatment modality can increase the longevity of the treatment to as long as 9 months. A serial puncture technique is used in this region for the deep and/or wider folds, while staying in the mid-dermis. Injection along the rhytide(s) is performed while the needle is being pulled out. The finer etched-in lines can be treated with a dermal-epidermal level injection of small-particle hyaluronic acid (or collagen), with a precise serial puncture technique and subsequent linear injec-

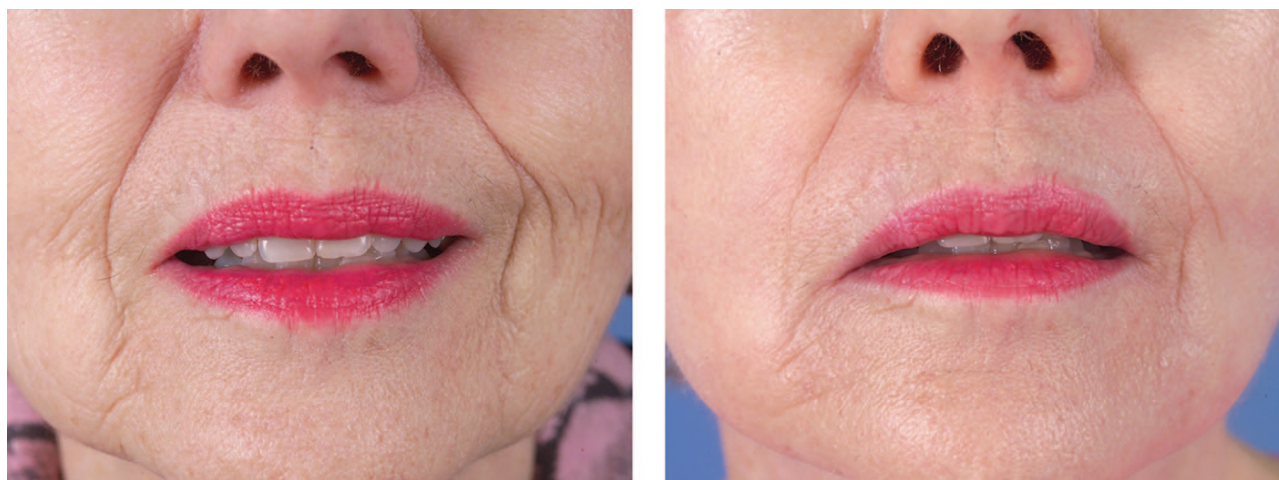

Fig. 11. Before and 6 months after 3 cc of Restylane was injected into the nasolabial folds and lips.

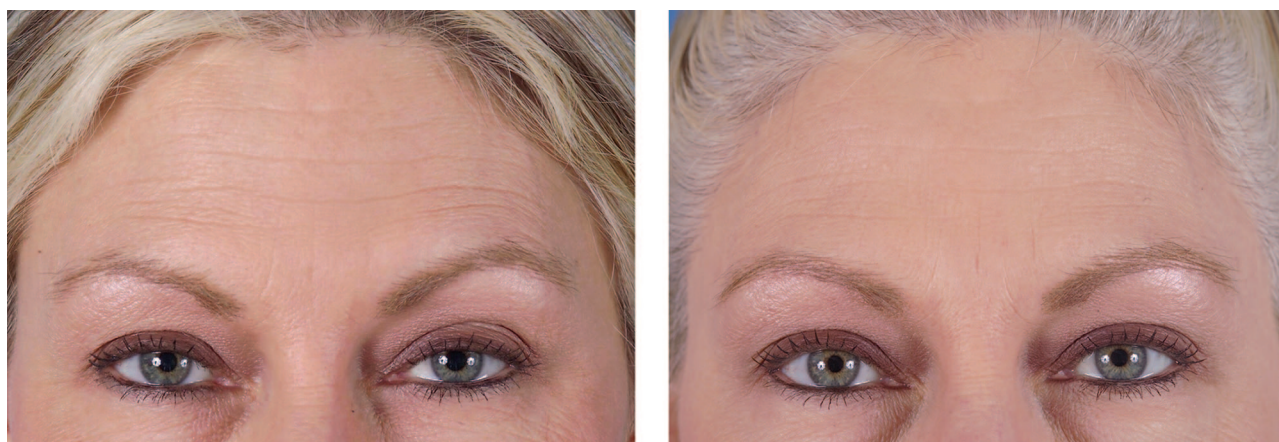

Fig. 12. Before and 6 months after combined treatment with Botox chemodenervation of the glabellar/brow depressor muscles and forehead and 0.5 cc of Restylane added to the glabellar lines.

tions to disrupt the fold and provide complete geometric filling. It is important to compress the supratrochlear vessels with the nondominant hand while injecting, to prevent inadvertent intravascular injection and minimize bruising. Approximately 0.5 cc is used per patient in this region.

Forehead Lines

The forehead is similar to the glabellar region, but a linear threading technique is better suited for this region. This is a highly dynamic area and is particularly amenable to coinjection with hyaluronic acid and Botox. Combined treatment will dramatically increase the longevity of the results, as previously stated. Once again, smaller-particle hyaluronic acid is indicated for dermal-epidermal injection of the finer etched-in furrows that remain despite Botox chemodenervation of the underlying musculature. Thin-skinned patients or

those previously injected with Botox may display filler visibility as lumps and irregularities.

As with other regions, using a layering technique and combining injection techniques can maximize the amount of correction achieved. The volume of filler necessary in this area depends on the depth and number of folds, which often relates to skin texture and thickness and whether the patient has received previous Botox treatment in this region. With very deep rhytides, the folds may need to be mechanically disrupted using a “pickle fork” before filling and chemodenervation. As mentioned previously, comprehensive treatment with hyaluronic acid fillers, Botox, and surgical facial rejuvenation techniques can provide powerful aesthetic results.

Tear Trough/Malar Region

This area, as with the nasolabial fold, can be further enhanced when augmentation is combined

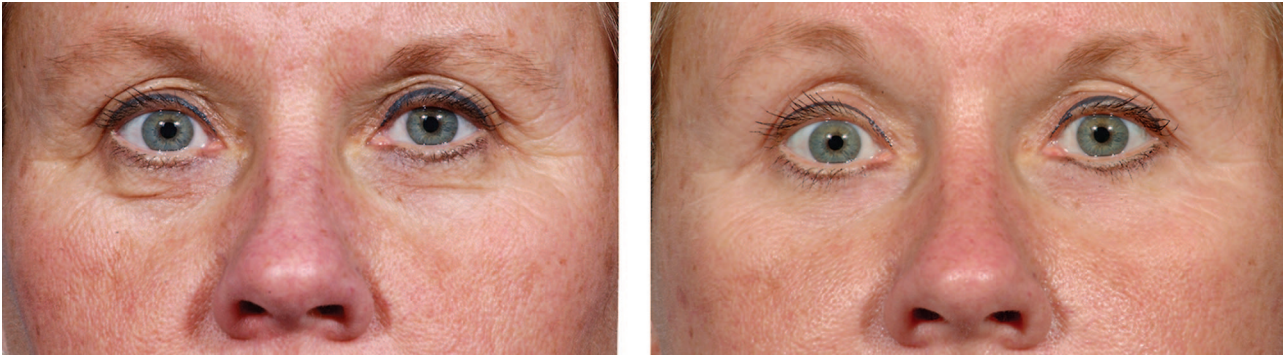


Fig. 13. Hyaluronic acid filler augmentation, along with secondary upper and lower blepharoplasty, to improve the tear trough (0.5 cc per side) and malar regions (0.5 cc per malar area bilaterally).

with a face lift or other surgical lift (Fig. 13). Although fat injections can be used easily in this area, along with surgical modalities, hyaluronic acid augmentation is an alternative that may be more predictable, with less risk of postinjection irregularities. This is particularly true of the tear trough region. Serial and linear threading is used in this region starting from a lateral to medial direction, with molding of the filler as one proceeds. The injection plane is supraperiosteal. Often, approximately 0.5 to 1.0 cc is all that is required in the tear trough region, but up to 2.0 cc of hyaluronic acid may be used for malar augmentation. The malar injection plane is also just superficial to the periosteum. Larger-particle hyaluronic acids, such as Perlane, once approved for use in the United States, will be especially useful for deeper augmentation planes.

Light massage of the area after injection allows the implanted material to conform to the contours of adjacent tissues. The tear trough region is prone to bruising because of the thin skin and increased vascularity of the periorbital area. Placing cold compresses over the area of injection for the first 24 hours can reduce ecchymosis and swelling.

POSTTREATMENT CARE

Massaging should preferably be performed by the injecting surgeon immediately after injection. We find it unpredictable and suboptimal to bequeath the molding and massaging to the patient. The use of cooling eye packs, such as Swiss Eye Therapy (Invotec International, Inc., Jacksonville, Fla.), for 20 minutes at a time in the first 24 to 48 hours can help decrease postinjection bruising and swelling. The patient's head should be elevated at approximately 30 degrees for the first 24 hours. Oral antihistamines can blunt the histamine release and resultant early edema and may be most useful in patients who develop more

edema than usual or redness immediately after injection.

Informed consent that describes the usual postinjection course should be reviewed with the patient before injection and can be re-reviewed by the surgeon and/or staff after treatment. Swelling may last up to 3 weeks, but it typically lasts 1 to 2 days. This can be particularly troublesome in the lips. Patients need to be informed that the lips may temporarily look overcorrected as a result of swelling. Bruising may last a little longer than a week and can be markedly minimized with cessation of aspirin, nonsteroidal anti-inflammatory drugs, and other, similar medications for 2 weeks before injection. Asymmetric animation may occur as a result of any local anesthetic that has been used and should be mentioned before injection of the local anesthetic. Discomfort is usually minimal. Nonsteroidal medication and any medications that can increase bruising should be avoided. A combination of cooling treatment and acetaminophen are typically all that is required. All patients should be seen within 2 weeks after treatment, so that touch-ups can be initiated if necessary. Hyaluronidase injections and/or massaging may help correct any irregular lumps and bumps that are visible and/or palpable (see Complications, below).

COMPLICATIONS

Potential adverse reactions are minimal and are mainly injection-related and self-resolving. These include local bruising, purpura, erythema, tenderness, itching, and swelling. A major adverse event that has been reported is hypersensitivity, but true immunoglobulin G- and E-mediated reactions are rare. Friedman et al.²⁷ reviewed the adverse events data on non-animal-based hyaluronic acid from 1999 to 2000 in Europe, Canada, Australia, South America, and Asia. They found

that of the 144,000 patients treated in 1999 and 262,000 treated in 2000, a reported 0.15 percent and 0.06 percent, respectively, experienced adverse events. The majority of these events were attributed to trace proteins found in prior lots of less purified product available at that time and included impurities of bacterial fermentation.

Two cases of injection site necrosis were reported and attributed to compression of the vascular supply from excessive use of the product at the time of injection.²⁷ Manna et al.²⁸ demonstrated transient adverse events in 12 to 13 percent of patients treated with Restylane and showed a higher protein load per milliliter of gel in Restylane versus Hylaform. However, no long-term sequelae resulted. The majority of these reports predate improved purification by manufacturers and therefore may not be relevant to the product line presently available.

Numerous reports have described a prolonged hypersensitivity with a granulomatous-like, foreign-body reaction.^{29–33} Biopsy specimens usually demonstrate a granulomatous foreign-body reaction with multinucleated cells surrounding a blue, amorphous material.^{29,30} Brody³⁰ reported a case involving a granulomatous-like reaction with persistent nodularity that was recalcitrant to a steroid regimen (injection and oral therapy) and antibiotic therapy, even at 5 months after injection. The nodularity finally responded to an injection of 15 U of hyaluronidase. Complete resolution without recurrence was noted within 24 hours. The hyaluronidase was prepared by diluting 0.5 cc of 150 U/cc (75 U) with 1.5 cc of 1% lidocaine with epinephrine.³⁰ Lambros³¹ and Vartanian et al.³⁴ have also reported on the benefits of hyaluronidase injection for both a chronic granulomatous-like reaction and misplacement of material. Hyaluronidase is a soluble protein enzyme that hydrolyzes hyaluronic acid by breaking the glucosamine bond between C1 of the glucosamine moiety and C4 of glucuronic acid.³⁰ It is often used to augment the affected area during injection of local anesthesia as well as to increase the hypotonic effect of local anesthesia in ophthalmologic procedures.³⁵ Although the bovine-derived hyaluronidase (Wydase; Wyeth-Lederle Pharmaceutical, Philadelphia, Pa.) is no longer available, recent forms of the drug have been approved by the U.S. Food and Drug Administration.

Large injection volumes can theoretically result in the formation of a sterile abscess,³⁶ although we have not witnessed this. Papulocystic nodules can develop and can be secondarily infected with frank pus.³³ Patients with prior telan-

giectasias can be prone to developing increased postinjection telangiectasias, and this should be discussed with the patient before treatment. Prolonged edema, if present, can be treated with a Medrol Dose pack (Pfizer, New York, N.Y.). Perhaps the most severe complication would be an intra-arterial injection, which can theoretically lead to blindness, but fortunately, this has never been reported.

Aesthetic complications include asymmetry, lumpiness, surface irregularities, undercorrection, and overcorrection. In our extensive experience, we have not observed any significant adverse reactions to injection with hyaluronic acid fillers.

CONCLUSIONS

Nonsurgical facial rejuvenation through soft-tissue augmentation with bioengineered hyaluronic acid derivatives has resulted in a major shift in the facial rejuvenation algorithm. With the increasing popularity of nonsurgical cosmetic procedures, new products aimed at soft-tissue augmentation and rejuvenation are being introduced every day that have different particle sizes, are more concentrated, and possess smaller protein loads. Hyaluronic acid fillers provide both patients and physicians with a biocompatible, easy-to-administer alternative that requires no preinjection skin testing and produces reproducible, long-lasting results. At our institution, we have experienced excellent results by combining soft-tissue augmentation with hyaluronic acid fillers, Botox, and surgical techniques to restore the youthful ideal facial aesthetic.

Rod J. Rohrich, M.D.

Department of Plastic Surgery

1801 Inwood Road

Dallas, Texas 75390-9132

rod.rohrich@utsouthwestern.edu

DISCLOSURE

The authors received no financial benefit from any commercial entity in support of this article.

REFERENCES

1. American Society of Plastic Surgeons. 2003 Statistics. Arlington Heights, Ill.: American Society of Plastic Surgeons. Available at http://www.plasticsurgery.org/public_education/loader.cfm?url=/commonspot/security/getfile.cfm&PageID=12552. Accessed August 8, 2007.
2. Rohrich, R. J., Rios, J. L., and Fagien, S. Role of new fillers in facial rejuvenation: A cautious outlook. *Plast. Reconstr. Surg.* 112: 1899, 2003.
3. Duranti, F., Salti, G., Bovani, B., et al. Injectable hyaluronic acid gel for soft tissue augmentation: A clinical and histological study. *Dermatol. Surg.* 24: 1317, 1998.

4. Laurent, T. C. Biochemistry of hyaluronan. *Acta Otolaryngol. Suppl.* 442: 7, 1987.
5. Devore, D. P., Hughes, E., and Scott, J. B. Effectiveness of injectable filler materials for smoothing wrinkle lines and depressed scars. *Med. Prog. Technol.* 20: 243, 1994.
6. Longas, M. O., Russell, C. S., and He, X. Y. Evidence for structural changes in dermatan sulfate and hyaluronic acid with aging. *Carbohydr. Res.* 159: 127, 1987.
7. Balasz, E. A., Bland, P. A., Denlinger, J. L., et al. Matriz engineering. *Blood Coagul. Fibrinolysis* 2: 173, 1991.
8. Balasz, E. A., Leshchiner, E., Larsen, N. E., et al. Hyaluronan biomaterials: Medical application. In D. L. Wise (Ed.), *Handbook of Biomaterials and Application*. New York: Dekker, 1995. Pp. 2719–2741.
9. Larsen, N. E., Pollak, C. T., Reiner, K., et al. Hylan gel biomaterial: Dermal and immunological compatibility. *J. Biomed. Mater. Res.* 27: 1129, 1993.
10. Laurent, T. C., and Fraser, J. R. Hyaluronan. *FASEB J.* 6:2397, 1992.
11. Q-Med AB. Restylane (Investigators Brochure). Uppsala, Sweden: Q-Med AB, 1996.
12. Melton, J. L., and Hanke, C. N. Soft tissue augmentation. In R. K. Roenigk and H. H. Roenigk (Eds.), *Dermatologic Surgery: Principles and Practice*. New York: Dekker, 1996. Pp. 1077–1087.
13. Captique (Package Insert). Santa Barbara, Calif.: Allergan, Inc. 2004. Available at http://facialplasticsurgery.lookingyourbest.com/articles/captique_faq.php. Accessed August 8, 2007.
14. U.S. Food and Drug Administration. Restylane. Available at www.fda.gov/cdrh/pdf4/p040024.html. Washington, D.C.: Food and Drug Administration. Accessed August 9, 2007.
15. U.S. Food and Drug Administration. Hylaform. Available at www.fda.gov/cdrh/mda/docs/p030032.html. Washington, D.C.: Food and Drug Administration. Accessed August 9, 2007.
16. Olenius, M. The first clinical study using a new biodegradable implant for the treatment of lips, wrinkles, and folds. *Aesthetic Plast. Surg.* 22: 97, 1998.
17. Narins, R. S. A randomized, double-blind, multicenter comparison of the efficacy and tolerability of Restylane versus Zyplast for the correction of nasolabial folds. *Dermatol. Surg.* 29: 588, 2003.
18. Restylane (Package Insert). Scottsdale, Ariz.: Medicis Aesthetics Holdings, Inc. 2003.
19. Restylane. Scottsdale, Ariz.: Medicis Aesthetics Holdings, Inc. Available at <http://restylaneusa.com>. Accessed August 9, 2007.
20. Hylaform (Package Insert). Santa Barbara, Calif.: Inamed. 2004.
21. Hylaform Plus (Package Insert). Santa Barbara, Calif.: Allergan, Inc. 2004.
22. Allergan/Inamed Web site. Available at <http://www.allerganandinamed.com>. Accessed August 9, 2007.
23. Carruthers, J., and Carruthers, A. A prospective, randomized, parallel group study analyzing the effect of BTX-A (Botox) and nonanimal sourced hyaluronic acid (NASHA, Restylane) in combination compared with NASHA (Restylane) alone in severe glabellar rhytides in adult female subjects: Treatment of severe glabellar rhytides with a hyaluronic acid derivative compared with the derivative and BTX-A. *Dermatol. Surg.* 29: 802, 2003.
24. Fitzpatrick, R. E., Goldman, M. P., Satur, N. M., and Tope, W. D. Pulsed carbon dioxide laser resurfacing of photo-aged facial skin. *Arch. Dermatol.* 132: 395, 1996.
25. Glogau, R. G. Aesthetic and anatomic analysis of the aging skin. *Semin. Cutan. Med. Surg.* 15: 134, 1996.
26. Lemperle, G., Holmes, R. E., Cohen, S. R., and Lemperle, S. M. A classification of facial wrinkles. *Plast. Reconstr. Surg.* 108: 1735, 2001.
27. Friedman, P. M., Mafong, E. A., Kauvar, A. N., and Geronemus, R. G. Safety data of injectable nonanimal stabilized hyaluronic acid gel for soft tissue augmentation. *Dermatol. Surg.* 28: 291, 2002.
28. Manna, F., Dentiui, M., Desisen, P., Depita, A., Mortilla, E., and Maras, B. Comparative chemical evaluation of two commercially available derivatives of hyaluronic acid (Hylaform from rooster combs and Restylane from *Streptococcus*) used for soft tissue augmentation. *J. Eur. Acad. Dermatol. Venereol.* 13: 183, 1999.
29. Fernandez-Acenero, M., Zamora, E., and Borbujo, J. Granulomatous foreign body reaction against hyaluronic acid: Report of a case after lip augmentation. *Dermatol. Surg.* 29: 12, 2003.
30. Brody, H. J. Use of hyaluronidase in the treatment of granulomatous hyaluronic acid reactions or unwanted hyaluronic acid misplacement. *Dermatol. Surg.* 31: 8, 2005.
31. Lambros, V. The use of hyaluronidase to reverse the effects of hyaluronic acid filler. *Plast. Reconstr. Surg.* 114: 277, 2004.
32. Micheels, P. Human anti-hyaluronic acid antibodies: Is it possible? *Dermatol. Surg.* 27: 2, 2001.
33. Lupton, J. R., and Alster, T. S. Cutaneous hypersensitivity reaction to injectable hyaluronic acid gel. *Dermatol. Surg.* 26: 2, 2000.
34. Vartanian, A. J., Frankel, A. S., and Rubin, M. G. Injected hyaluronidase reduces Restylane-mediated cutaneous augmentation. *Arch. Facial Plast. Surg.* 7: 231, 2005.
35. McEvoy, G. K. (Ed.). Hyaluronidase. In *AHFS Drug Information 2001*. Bethesda, Md.: American Society of Health-Systems Pharmacists, 2001. P. 2602.
36. Shafir, R., Amir, A., and Gur, E. Long-term complications of facial injection with Restylane. *Plast. Reconstr. Surg.* 106: 1215, 2000.