

# Anatomy of the Corrugator Supercilii Muscle: Part I. Corrugator Topography

Jeffrey E. Janis, M.D.  
Ashkan Ghavami, M.D.  
Joshua A. Lemmon, M.D.  
Jason E. Leedy, M.D.  
Bahman Guyuron, M.D.  
Dallas, Texas; and Cleveland, Ohio

**Background:** Complete corrugator supercilii muscle resection is important for the surgical treatment of migraine headaches and may help prevent postoperative abnormalities in surgical forehead rejuvenation. Specific topographic analysis of corrugator supercilii muscle dimensions and its detailed association with the supraorbital nerve branching patterns has not been thoroughly delineated. Part I of this two-part study aims to define corrugator supercilii muscle topography with respect to external bony landmarks.

**Methods:** Twenty-five fresh cadaver heads (50 corrugator supercilii muscles and 50 supraorbital nerves) were dissected to isolate the corrugator supercilii muscle from surrounding muscles. Standardized measurements of corrugator supercilii muscle dimensions were taken with respect to the nasion and lateral orbital rim.

**Results:** Relative to the nasion, the most medial origin of the corrugator supercilii muscle was found at  $2.9 \pm 1.0$  mm; the most lateral origin point,  $14.0 \pm 2.8$  mm. The lateralmost insertion of the corrugator supercilii muscle measured  $43.3 \pm 2.9$  mm from the nasion or  $7.6 \pm 2.7$  mm medial to the lateral orbital rim. The most cephalic extent (apex) of the muscle was located  $32.6 \pm 3.1$  mm cephalad to the nasion–lateral orbital rim plane and  $18.0 \pm 3.7$  mm medial to the lateral orbital rim. There were no statistical differences noted between the right and left sides.

**Conclusions:** The dimensions of the corrugator supercilii muscle are more extensive than previously described and can be easily delineated using fixed bony landmarks. These data may prove beneficial in performing safe, complete, and symmetric corrugator supercilii muscle resection for forehead rejuvenation and for effective decompression of the supraorbital nerve and supratrochlear nerve branches in the surgical treatment of migraine headaches. (*Plast. Reconstr. Surg.* 120: 1647, 2007.)

Complete resection of the corrugator supercilii muscle has been advocated for both forehead rejuvenation and in the surgical treatment of migraine headaches.<sup>1-3</sup> Unequal corrugator supercilii muscle removal and/or incomplete corrugator supercilii muscle resection after forehead rejuvenation can lead to undesirable sequelae such as dimpling, depressions, and residual corrugator activity, with resultant persis-

tence of dynamic rhytides.<sup>1-3</sup> All of these may become exaggerated on forehead animation.<sup>1,4,5</sup> The cause of this may be related to the surgical approach, specific technical execution, and/or the surgeon's experience with a particular technique.<sup>1,6,7</sup>

In a recent study, Walden et al.<sup>6</sup> have shown that the amount of corrugator supercilii muscle resection can vary depending on the approach used, with as much as one-third of the transverse corrugator supercilii muscle head remaining after transpalpebral attempts at complete muscle removal. Although the senior author (B.G.) believes that this may largely be technique-related,<sup>7,8</sup> familiarity with normal corrugator supercilii muscle dimensions in reference to fixed bony landmarks can minimize this unpredictability and allow for a more systematic approach to precise corrugator supercilii muscle myectomy. In addition, a comprehensive understanding of the corrugator supercilii

From the Department of Plastic Surgery, The University of Texas Southwestern Medical Center, and the Department of Plastic and Reconstructive Surgery, Case Western Reserve University School of Medicine.

Received for publication April 13, 2006; accepted September 7, 2006.

Gaspar W. Anastasi Award presentation at the American Society for Aesthetic Plastic Surgery Annual Meeting, in Orlando, Florida, April 23, 2006.

Copyright ©2007 by the American Society of Plastic Surgeons

DOI: 10.1097/01.prs.0000282725.61640.e1

muscle dimensions may assist less experienced surgeons in obtaining a successful outcome when performing any of the numerous surgical approaches for forehead rejuvenation that have been described.

Migraine headaches have been postulated to be associated with peripheral nerve trigger points.<sup>9-14</sup> The supraorbital/supratrochlear nerves have been implicated as one of four peripheral trigger sites that potentially account for migraine headache symptomatology.<sup>10</sup> Improvement or complete amelioration of migraine headaches has been demonstrated after chemodenervation of the corrugator supercilii muscle by botulinum toxin type A,<sup>9,10</sup> which is theorized to act by decompression of the supraorbital nerve and supratrochlear nerve by relaxation of the investing musculature.<sup>10,14</sup> Long-term success has been demonstrated in a vast majority of patients who have subsequently gone on to have complete corrugator supercilii muscle myectomy.<sup>10</sup>

Based on extensive intraoperative observation, the senior author (B.G.) postulates that the supraorbital nerve branches demonstrate a more significant investment pattern in relation to the corrugator supercilii muscle fibers, further supporting the necessity for safe and complete resection of the corrugator supercilii muscle for supraorbital nerve decompression in migraine treatment. Although the investing topography of other peripheral trigger points has been described,<sup>9,11-13</sup> the supraorbital nerve and its close relationship to the corrugator supercilii muscle fibers requires further anatomical inspection. A comprehensive understanding of corrugator supercilii muscle dimensions and its relationship with the supraorbital nerve branching patterns may improve the safety and predictability of forehead rejuvenation and surgical treatment for migraine headaches. In Part I of this study, the topographic dimensions of the corrugator supercilii muscle with respect to fixed external bony landmarks are defined, whereas in Part II, the branching patterns of the supraorbital nerve as they relate to the corrugator supercilii muscle fibers are described.

### RELEVANT ANATOMY

The corrugator supercilii muscle is one of the three commonly described brow depressor muscle groups (including the medial orbicularis oculi and depressor supercilii) and is composed of two heads. The transverse head originates from the superomedial aspect of the orbital rim to insert into the dermis at the middle third of the brow

while interdigitating with the orbicularis oculi muscle and frontalis muscles. The oblique head of the corrugator supercilii muscle is smaller, with its fibers commonly running parallel to those of the depressor supercilii muscle after insertion into the medial brow.

Knize<sup>15</sup> dissected 40 hemifacial cadaver heads to evaluate the detailed muscular anatomy of the forehead region. The origin of the corrugator supercilii muscle was found to be consistent and located at the frontal bone near the superomedial orbital rim, anterior and slightly cephalad to the trochlea of the extraocular superior oblique muscle.<sup>15</sup> The corrugator supercilii muscle fibers then pass superolaterally "through" the frontalis and orbicularis oculi muscles before inserting into the medial half of brow skin.<sup>15</sup> The corrugator supercilii muscle also extends through the galeal fat pad before giving off its dermal insertions.<sup>15</sup> It is unclear from these and other descriptions whether the corrugator supercilii muscle extends beyond the temporal fusion line, and exactly how lateral the insertion point is.<sup>16,17</sup>

In a recent report that examined the efficacy of the transpalpebral, endoscopic, and open coronal approaches to corrugator supercilii muscle resection, the transverse head of the corrugator supercilii muscle was found to be incompletely resected, mostly in the lateral region using the transpalpebral approach.<sup>6</sup> The authors noted that the transverse head of the corrugator muscle was longer and thicker (average, 7.5 mm) than the oblique head (2.0 mm).<sup>6</sup> More complete resection of the corrugator, along with the depressor supercilii and procerus muscles, was seen with the endoscopic approach. In addition, the authors noted the utility of visual cues such as muscle color to differentiate between the various muscle fibers.<sup>6</sup> For example, the medial orbicularis oculi is superficial and a lighter pink than the vertically oriented red depressor supercilii muscle fibers.<sup>6</sup> Isse and Elahi<sup>17</sup> performed a smaller cadaver study and found that in the lateral two-thirds of the brow, the corrugator supercilii muscle fibers pass *through* the orbicularis oculi and frontalis muscles. This most lateral region of the corrugator supercilii muscle, although difficult to dissect, is important because it may largely account for lateral brow depressions seen postoperatively.<sup>17,18</sup>

The motor nerve supply to the corrugator supercilii muscle is from the frontal branch of the temporal division of the facial nerve, whereas the zygomatic branch seems to innervate the oblique head.<sup>2</sup> Postoperative observation of corrugator supercilii muscle reactivation after lat-

eral resection provides evidence that motor nerve fibers originating medially exist and are involved in reinnervation.<sup>1,2,15</sup> This further supports the importance of *complete* corrugator supercilii muscle resection for supraorbital nerve/supratrochlear nerve decompression in the surgical treatment of migraine headaches and for forehead rejuvenation, when indicated.

The association of the supratrochlear nerve with the corrugator supercilii muscle is well known, as it exits just lateral to the corrugator supercilii muscle origin, enters the muscle (where it divides into three or four small branches), courses in a cephalad direction just deep to the anterior surface of the corrugator, and then penetrates the frontalis muscle.<sup>2,19</sup> However, the intimate relationship of the supraorbital nerve with the corrugator supercilii muscle has not been specifically elucidated.

Based on previous reports,<sup>15,20</sup> the supraorbital nerve does not seem to run within the corrugator muscle mass. However, in a study by Knize,<sup>15</sup> cross-sectional histology performed in two cadavers revealed the presence of muscle fiber staining deep to the supraorbital nerve (likely corrugator supercilii muscle fibers). This may suggest a more intimate relationship between the supraorbital nerve and corrugator supercilii muscle fibers than previously thought. This intricacy is important and will be examined further in Part II of our study.

## MATERIALS AND METHODS

Twenty-five fresh cadaver heads (50 corrugator muscles and 50 supraorbital nerves) were dissected using a cross-shaped incision centered over the radix, with the transverse component follow-

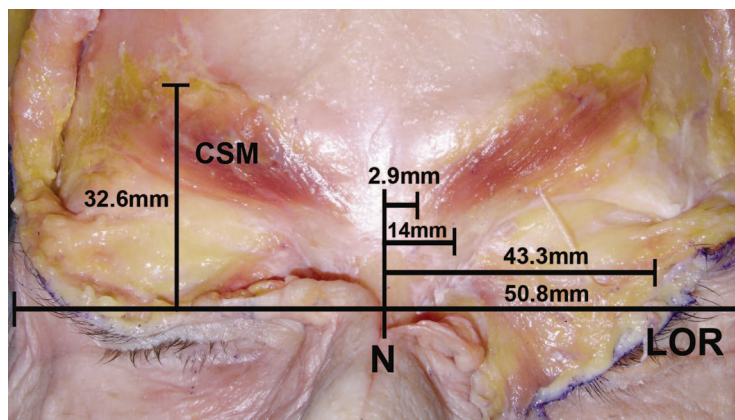
ing the eyebrow arches. The frontalis and depressor supercilii muscles were dissected off of the corrugator supercilii muscle and elevated along with the skin flaps. Once the full extent of the transverse and oblique heads of the corrugator supercilii muscle were well delineated, the nasion and lateral orbital rim apex (most lateral bony point) were marked, and standardized measurements of muscle dimensions were taken.

Because of the globe distortion and soft-tissue changes present in cadaver specimens, soft-tissue reference points were not used. In addition, use of soft-tissue landmarks may result in great variability *in vivo*. Therefore, fixed bony landmarks were chosen as reference points.

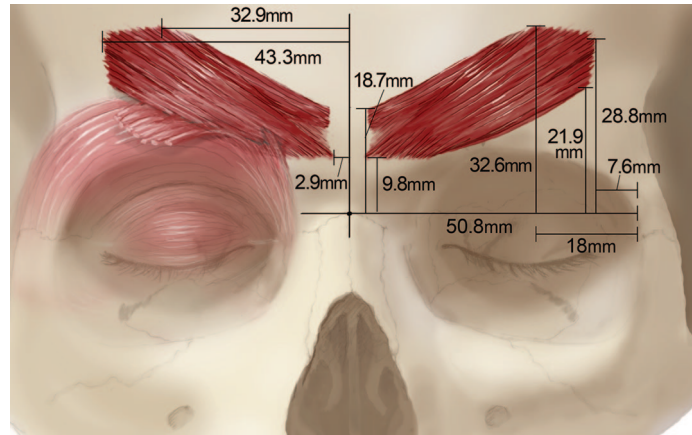
Vertical muscle dimensions were measured in reference to a horizontal line created to transect the lateral orbital rim and nasion points of reference. Horizontal muscle dimensions were measured relative to a vertical line bisecting the nasion, anterior nasal spine, and menton. Results are listed as mean values with standard deviations. Mean values between the right and left sides were compared using paired *t* test analysis.

## RESULTS

There was no statistical difference seen between the right and left corrugator supercilii muscle dimensions based on paired *t* test analysis ( $p < 0.0001$ ); therefore, right ( $n = 25$ ) and left ( $n = 25$ ) corrugator supercilii muscle measurements were added (total  $n = 50$ ) to improve the power of the study and are provided as mean values with corresponding standard deviations. All measurements were obtained using millimeters as the unit of measurement (Figs. 1 and 2). Horizontal cor-



**Fig. 1.** Corrugator supercilii muscle (CSM) topography; cadaver dissection with average distances. Cadaver dissection of the corrugator supercilii muscle showing the major data points that delineate muscle dimensions with respect to the nasion (N) and lateral orbital rim (LOR).



**Fig. 2.** Comprehensive corrugator supercilii muscle dimensions. Artistic rendition (proportionate scale) of all the measured data points of the corrugator supercilii muscle in relation to the palpable bony anatomy [nasion (*N*) and lateral orbital rim (*LOR*)]. Note reflection of muscular interdigitation required to delineate the lateral extent of the corrugator supercilii muscle.

rugator supercilii muscle dimensions were measured first. The vertical midline connecting the nasion and anterior nasal spine was used as the reference landmark for all horizontal muscle dimension points (Table 1).

The nasion to lateral orbital rim distance measured  $50.8 \pm 2.9$  mm (range, 46 to 59 mm). The most lateral insertion point of the corrugator supercilii muscle measured  $43.3 \pm 2.9$  mm from the nasion, which corresponds to a value that is 85 percent of the distance to the lateral orbital rim. This is equivalent to a distance of  $7.6 \pm 2.7$  mm medial to the lateral orbital rim (Table 2).

The medial origin of the corrugator muscle was located  $2.9 \pm 1.0$  mm from the nasion, whereas the lateral origin point measured  $14.0 \pm 2.8$  mm from the nasion. This corresponds to an average origin width of 11.1 mm. The apex (most cephalad point) of the corrugator supercilii mus-

**Table 2. Topographic Dimensions of the Corrugator Supercilii Muscle Lateral Orbital Rim Reference Points (Mean Values)**

	Right (mm)	Left (mm)	Overall (mm)
LOR to apex	$17.9 \pm 3.3$	$18.0 \pm 2.5$	$18.0 \pm 3.7$
LOR to lateral extent	$6.9 \pm 2.6$	$8.3 \pm 3.2$	$7.6 \pm 2.7$

LOR, the most medial palpable point of the lateral orbital rim.

cle was located  $32.9 \pm 2.6$  mm lateral to the nasion or  $18.0 \pm 3.7$  mm medial to the lateral orbital rim. Vertical dimensions were measured in reference to a straight horizontal plane that passes through the nasion and lateral orbital rim (Table 3).

The apex (most cephalad point) of the muscle was located at a mean distance of  $32.6 \pm 3.1$  mm from the horizontal plane. The vertical height of

**Table 1. Topographic Dimensions of the Corrugator Supercilii Muscle Nasion Reference Points (Mean Values)**

	Right (mm)	Left (mm)	Overall (mm)
Nasion to lateral orbital rim	$50.9 \pm 2.9$	$50.8 \pm 2.8$	$50.8 \pm 2.9$
Nasion to medial origin	$2.7 \pm 0.9$	$3.0 \pm 1.0$	$2.9 \pm 1.0$
Nasion to lateral origin	$13.8 \pm 3.0$	$14.2 \pm 2.6$	$14 \pm 2.8$
Nasion to lateral extent	$44 \pm 2.6$	$42.7 \pm 3.5$	$43.3 \pm 2.9$
Nasion to apex*	$33.0 \pm 2.8$	$32.5 \pm 2.0$	$32.9 \pm 2.6$

\*The most cephalad extent of corrugator supercilii muscle fibers.

**Table 3. Topographic Dimensions of the Corrugator Supercilii Muscle Vertical Reference Points (Mean Values)**

	Right (mm)	Left (mm)	Overall (mm)
Plane to medial-inferior*	$9.8 \pm 2.1$	$9.3 \pm 2.0$	$9.8 \pm 2.2$
Plane to medial-superior	$18.6 \pm 2.4$	$18.2 \pm 2.5$	$18.7 \pm 2.4$
Plane to lateral-inferior	$22.3 \pm 3.2$	$21.1 \pm 3.7$	$21.9 \pm 3.3$
Plane to lateral-superior	$28.9 \pm 2.8$	$26.8 \pm 3.5$	$28.8 \pm 3.5$
Plane to apex	$32.8 \pm 3.1$	$31.6 \pm 2.5$	$32.6 \pm 3.1$

\*Plane represents a straight horizontal reference line that passes through the nasion and lateral orbital rim points.

the most medial-inferior muscle origin was  $9.8 \pm 2.2$  mm and  $18.7 \pm 2.42$  mm medial-superior. Lateral heights are  $21.9 \pm 3.3$  mm lateral-inferior and  $28.8 \pm 3.5$  mm lateral-superior.

## DISCUSSION

Complete resection of the corrugator supercilii muscle has been advocated for both forehead rejuvenation<sup>1-3</sup> and for the surgical treatment of migraine headaches.<sup>6,9</sup> However, incomplete and/or unequal corrugator supercilii muscle resection with simple, imprecise debulking procedures can have deleterious consequences. These include forehead/brow asymmetries, skin dimpling (particularly with animation), and recurrence of glabellar furrows and frown lines.<sup>1,2,15</sup> In addition, aberrant reinnervation of residual muscle can result in awkward forehead animation.<sup>1,2,4</sup> Irregular “lateral horns” of reinnervated muscle mass can become evident as early as 3 to 4 months postoperatively.<sup>4</sup>

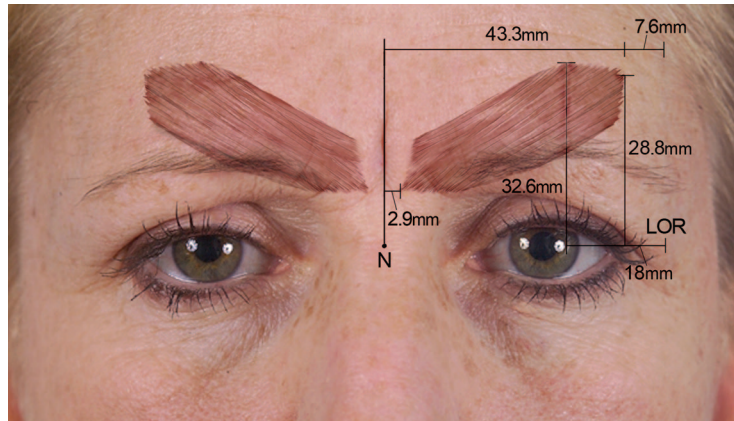
The variability and unpredictability of complete corrugator supercilii muscle resection may also hinder successful surgical treatment of migraine headaches, as *complete* peripheral nerve (supraorbital nerve and supratrochlear nerve) decompression is mandatory.<sup>9,10</sup> In our current report, we set out to further refine our understanding of the average dimensions of the corrugator supercilii muscle with respect to easily identifiable, fixed bony landmarks. To our knowledge, this is the largest cadaver study looking at corrugator supercilii muscle anatomy. This detailed topographic information can assist the surgeon in more accurate preoperative planning and improved perioperative confirmation of complete corrugator supercilii muscle resection.

Clinically, incomplete corrugator supercilii muscle resection of up to 50 percent has been reported with some techniques.<sup>6,8</sup> In a recent detailed anatomical study, Walden et al.<sup>6</sup> have demonstrated that up to one-third (most lateral aspect) of the transverse corrugator supercilii muscle head remained after transpalpebral resection that was otherwise thought to be complete. Guyuron<sup>7</sup> offers three plausible causes for suboptimal corrugator supercilii muscle resection: (1) interdigitations with the frontalis and orbicularis muscles may inhibit thorough visual assessment of the superior aspect of the transverse head; (2) fear of damage to the supraorbital nerve; and (3) the full extent of the lateralmost portion of the corrugator supercilii muscle is underestimated. Knize<sup>2</sup> recommends complete avulsion of the corrugator supercilii muscle origin medially, and re-

section to where the corrugator supercilii muscle passes into the frontalis/orbicularis muscles laterally, to prevent possible reinnervation from other motor branches, such as the frontal branch of the facial nerve or from medial nerve fibers.

Although the endoscopic approach is the more commonly described approach for surgical treatment of migraine headaches,<sup>10</sup> multiple surgical techniques have been described for brow depressor muscle excision and forehead rejuvenation. These mainly include the transpalpebral, endoscopic, and coronal approaches. Accuracy in brow depressor muscle (including corrugator supercilii muscle) resection has been clearly shown to be influenced by the surgical approach.<sup>6</sup> Through this study, specific data regarding the most lateral, medial, superior, and inferior borders of the corrugator supercilii muscle are now available and may increase the accuracy of performing more precise corrugator supercilii muscle resection regardless of the surgical approach. In addition, information regarding supraorbital nerve branching patterns provided in Part II of the current study will further refine our knowledge regarding the intimate relationship between the supraorbital nerve and corrugator supercilii muscle.

Based on extensive intraoperative observation, the senior author (B.G.) has noted that corrugator supercilii muscle dimensions are more extensive than previously reported. Knize<sup>2</sup> describes the corrugator supercilii muscle origin as being constant, with both a transverse and oblique head, whereas the remainder of the muscle mass is variable. Inadequate removal of the lateral portion of the transverse head of the corrugator supercilii muscle noted by Walden et al.<sup>6</sup> suggests that the dissection of the most lateral insertion point of the corrugator supercilii muscle is most unpredictable. We found this point to measure  $43.3 \pm 2.9$  mm from the nasion (located 85 percent of the distance to the lateral orbital rim), or  $7.6 \pm 2.7$  mm medial to the lateral orbital rim. This point was not easily identifiable and required meticulous dissection (using  $3.8\times$  loupe magnification) off of the interdigitating orbicularis oculi muscles, frontalis muscle, and eyebrow dermis (Fig. 2). In addition, this most lateral portion of the corrugator supercilii muscle is thinner and more superficial; therefore, care must be taken to avoid inadvertent frontalis and orbicularis oculi muscle injury during resection. The improved understanding of this ambiguous point of muscular interdigitation allows for a more precise and tailored approach to corrugator supercilii muscle removal.



**Fig. 3.** Most clinically relevant dimensions. Patient photograph depicts the more clinically useful topographic data points. Horizontal data points: medialmost corrugator supercilii muscle origin (2.9 mm); lateralmost extension point (43.3 mm from the nasion and 7.6 mm from the lateral orbital rim); location of apex from lateral orbital rim (18 mm). Vertical data points (from nasion to lateral orbital rim plane): apex (32.6 mm) and lateralmost extent of corrugator supercilii muscle (28.8 mm).

We did not observe a clear delineation between the oblique and transverse head fibers, as the fibers quickly paralleled each other within the mass of the corrugator supercilii muscle after the origin of the oblique head was no longer seen. This may indicate that there is a singular corrugator supercilii muscle mass, possibly with variable or accessory muscle fiber origins without well-defined and separate heads.

We found an average muscle origin width of 11.1 mm, with the medialmost origin of the oblique head of the corrugator supercilii muscle located  $2.9 \pm 1.0$  mm from the nasion and  $9.8 \pm 2.2$  mm cephalad to the horizontal plane and the lateralmost origin point located  $14.0 \pm 2.8$  mm lateral to the nasion. The apex (most cephalad point) of the corrugator supercilii muscle was located  $32.9 \pm 2.6$  mm lateral to the nasion at a mean height of  $32.6 \pm 3.1$  mm from the horizontal plane. This apex point is crucial for performing accurate and complete chemodenervation of the corrugator supercilii muscle with botulinum toxin. A comprehensive technical approach that involves a more thorough chemodenervation of all the corrugator supercilii muscle fibers is required for both the diagnosis of frontal peripheral trigger points and in the definitive surgical treatment of migraine headaches.<sup>10</sup> If the most cephalad extent of the corrugator supercilii muscle is not adequately treated, the successful treatment of migraine symptoms may suffer.

The current report found the corrugator supercilii muscle dimensions to be consistent

and symmetric between left and right sides. Although palpation of a contracted corrugator supercilii muscle on forehead animation may provide approximate muscle dimensions in the clinical setting and should be a part of the preoperative examination, objective topographic points based on fixed bony landmarks more accurately define the extent of the corrugator supercilii muscle mass to be resected. This information can potentially be used to plan a more systematic approach to complete corrugator supercilii muscle removal by providing a “surgical roadmap” as to the anatomical limits required for precise surgical excision of the corrugator supercilii muscle, regardless of the technique used (Fig. 3).

Although *complete* muscle resection is indicated for migraine surgery, differential preservation of muscle and selective release of periosteum and brow retaining ligaments may be required for a more individualized approach to forehead rejuvenation.<sup>1,21–23</sup> This should be based on the surgeon’s preoperative evaluation of each patient’s specific forehead morphology.<sup>1,21,23–25</sup> Knowledge of the corrugator supercilii muscle topography can further assist in selective retention of portions of the corrugator supercilii muscle mass or retaining ligaments when indicated. Other glabellar muscles were not evaluated; however, future studies using histologic analysis are needed to better define regional muscles such as the medial portion of the orbicularis oculi muscle and depressor supercilii muscle.

## CONCLUSIONS

The dimensions of the corrugator supercilii muscle were found to extend more lateral and superior and displayed a greater width of origin than previously described. In addition, a clear distinction between the oblique and transverse fibers was not seen. Complete corrugator supercilii resection for forehead rejuvenation (when indicated) and for supraorbital nerve (and supratrochlear nerve) decompression in migraine headache treatment can be safely and more precisely accomplished with the aid of external bony landmarks. By performing a more systematic approach to corrugator supercilii muscle resection, the risk of undesirable postoperative outcomes such as forehead irregularities, asymmetries, and unequal muscle reactivation may decrease. In addition, the learning curve for performing successful forehead rejuvenation and surgical treatment of migraine headaches by means of numerous surgical approaches may be improved with more accurate knowledge of the topographic information provided in this study. In Part II of this study, a more refined description of the supraorbital nerve branching patterns as they pertain to the corrugator supercilii muscle mass will be described.

**Jeffrey E. Janis, M.D.**

Department of Plastic Surgery  
The University of Texas Southwestern Medical Center  
1801 Inwood Road, WA4.240  
Dallas, Texas 75390-9132  
jeffrey.janis@utsouthwestern.edu

## ACKNOWLEDGMENT

*The authors thank Rod J. Rohrich, M.D., for the generous donation of the cadaver specimens used in this study.*

## DISCLOSURE

*None of the authors received financial benefits from any commercial entity in support of this article.*

## REFERENCES

- Guyuron, B. Endoscopic forehead rejuvenation: Limitations, flaws, and rewards. *Plast. Reconstr. Surg.* 117: 1121, 2006.
- Knize, D. M. Transpalpebral approach to the corrugator supercilii and procerus muscles. *Plast. Reconstr. Surg.* 95: 52, 1995.
- Guyuron, B., Michelow, B. J., and Thomas, T. Corrugator supercilii muscle resection through blepharoplasty incision. *Plast. Reconstr. Surg.* 95: 691, 1995.
- Knize, D. M. Muscles that act on glabellar skin: A closer look. *Plast. Reconstr. Surg.* 105: 350, 2000.
- Macdonald, M. R., Spiegall, J. H., Raven, R. B., Kabaker, S. S., and Mass, C. S. An anatomical approach to glabellar rhytids. *Arch. Otolaryngol. Head Neck Surg.* 124: 1315, 1998.
- Walden, J. L., Brown, C. C., Klapper, A. J., Chia, C. T., and Aston, S. J. An anatomical comparison of transpalpebral, endoscopic, and coronal approaches to demonstrate exposure and extent of brow depressor muscle resection. *Plast. Reconstr. Surg.* 116: 1479, 2005.
- Guyuron, B. An anatomical comparison of transpalpebral, endoscopic, and coronal approaches to demonstrate exposure and extent of brow depressor muscle resection (Discussion). *Plast. Reconstr. Surg.* 116: 1488, 2005.
- Jelks, G. Transpalpebral corrugator/depressor resection. Presented at the *Aesthetic Surgery of the Aging Face Symposium*, New York, N.Y., November 22, 2003.
- Guyuron, B., Varghai, A., Michelow, B. J., Thomas, T., and Davis, J. Corrugator supercilii muscle resection and migraine headaches. *Plast. Reconstr. Surg.* 106: 429, 2000.
- Guyuron, B., Kriegler, J. S., Davis, J., and Amini, S. B. Comprehensive surgical treatment of migraine headaches. *Plast. Reconstr. Surg.* 115: 1, 2005.
- Mosser, S. W., Guyuron, B., Janis, J. E., and Rohrich, R. J. The anatomy of the greater occipital nerve: Implications for the etiology of migraine headaches. *Plast. Reconstr. Surg.* 113: 693, 2004.
- Dash, K. S., Janis, J. E., and Guyuron, B. The lesser occipital nerves and migraine headaches. *Plast. Reconstr. Surg.* 115: 1752, 2005.
- Totonchi, A., Pashmini, N., and Guyuron, B. The zygomaticotemporal branch of the trigeminal nerve: An anatomical study. *Plast. Reconstr. Surg.* 115: 273, 2005.
- Austad, E. D. Comprehensive surgical treatment of migraine headaches (Discussion). *Plast. Reconstr. Surg.* 115: 1759, 2005.
- Knize, D. M. An anatomically based study of the mechanism of eyebrow ptosis. *Plast. Reconstr. Surg.* 97: 1321, 1996.
- Park, J. I., Hoagland, T. M., and Park, M. S. Anatomy of the corrugator supercilii muscle. *Arch. Facial Plast. Surg.* 5: 412, 2003.
- Isse, N. G., and Elahi, M. M. The corrugator supercilii muscle revisited. *Aesthetic Surg. J.* 21: 209, 2001.
- Knize, D. M. The corrugator supercilii muscle revisited (Discussion). *Aesthetic Surg. J.* 21: 214, 2001.
- Williams, P. L., Warwick, R., Dyson, M., and Bannister, L. H. (Eds.). *Gray's Anatomy*, 37th Ed. London: Churchill Livingstone, 1989. P. 1100.
- Knize, D. M. A study of the supraorbital nerve. *Plast. Reconstr. Surg.* 96: 564, 1995.
- Sullivan, P. E., Salomon, J. A., Woo, A. S., and Freeman, M. B. The importance of the retaining ligamentous attachments of the forehead for selective eyebrow reshaping and forehead rejuvenation. *Plast. Reconstr. Surg.* 117: 95, 2006.
- Moss, C. J., Mendelson, B. C., and Taylor, G. I. Surgical anatomy of the ligamentous attachments in the temple and periorbital regions. *Plast. Reconstr. Surg.* 105: 1475, 2000.
- Abramo, C. A., and Dorta, A. A. Selective myotomy in forehead endoscopy. *Plast. Reconstr. Surg.* 112: 873, 2003.
- Freund, R. M., and Nolan, W. B., III. Correlation between browlift outcomes and aesthetic ideals for eyebrow height and shape in females. *Plast. Reconstr. Surg.* 97: 1343, 1996.
- Byrd, H. S., and Andochick, S. E. The deep temporal lift: A multiplanar, lateral brow, temporal, and upper face lift. *Plast. Reconstr. Surg.* 97: 928, 1996.